This is a digital copy of a book that was preserved for generations on library shelves before it was carefully scanned by Google as part of a project to make the world's books discoverable online.

It has survived long enough for the copyright to expire and the book to enter the public domain. A public domain book is one that was never subject to copyright or whose legal copyright term has expired. Whether a book is in the public domain may vary country to country. Public domain books are our gateways to the past, representing a wealth of history, culture and knowledge that's often difficult to discover.

Marks, notations and other marginalia present in the original volume will appear in this file - a reminder of this book's long journey from the publisher to a library and finally to you.

Usage guidelines

Google is proud to partner with libraries to digitize public domain materials and make them widely accessible. Public domain books belong to the public and we are merely their custodians. Nevertheless, this work is expensive, so in order to keep providing this resource, we have taken steps to prevent abuse by commercial parties, including placing technical restrictions on automated querying.

We also ask that you:

+ *Make non-commercial use of the files* We designed Google Book Search for use by individuals, and we request that you use these files for personal, non-commercial purposes.

+ *Refrain from automated querying* Do not send automated queries of any sort to Google's system: If you are conducting research on machine translation, optical character recognition or other areas where access to a large amount of text is helpful, please contact us. We encourage the use of public domain materials for these purposes and may be able to help.

+ *Maintain attribution* The Google "watermark" you see on each file is essential for informing people about this project and helping them find additional materials through Google Book Search. Please do not remove it.

+ *Keep it legal* Whatever your use, remember that you are responsible for ensuring that what you are doing is legal. Do not assume that just because we believe a book is in the public domain for users in the United States, that the work is also in the public domain for users in other countries. Whether a book is still in copyright varies from country to country, and we can't offer guidance on whether any specific use of any specific book is allowed. Please do not assume that a book's appearance in Google Book Search means it can be used in any manner anywhere in the world. Copyright infringement liability can be quite severe.

About Google Book Search

Google's mission is to organize the world's information and to make it universally accessible and useful. Google Book Search helps readers discover the world's books while helping authors and publishers reach new audiences. You can search through the full text of this book on the web at `http://books.google.com/`

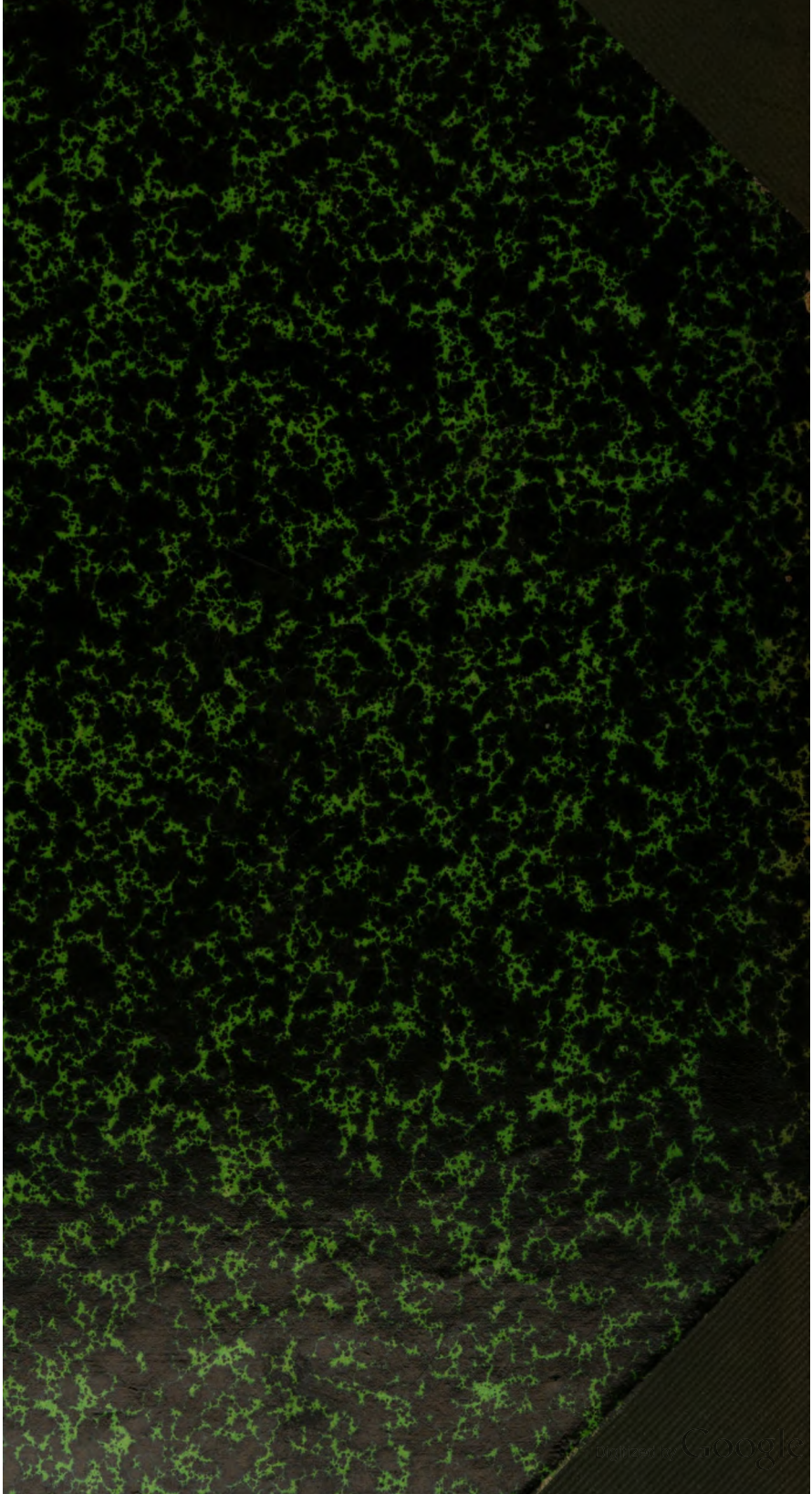

BOSTON
MEDICAL LIBRARY
8 THE FENWAY

Digitized by Google

Digitized by Google

Digitized by Google

Digitized by Google

Digitized by Google

PROCEEDINGS

OF THE

PATHOLOGICAL SOCIETY

OF PHILADELPHIA

NEW SERIES, VOLUME XIX
OLD SERIES, VOLUME XXXVII

CONTAINING THE TRANSACTIONS OF THE SOCIETY FROM JANUARY, 1916, TO JANUARY, 1917

EDITED BY

JOHN A. KOLMER, M.D.

RECORDER OF THE SOCIETY

PHILADELPHIA

PRINTED FOR THE SOCIETY BY WM. J. DORNAN

1917

Digitized by Google

OFFICERS AND COMMITTEES

OF THE

PATHOLOGICAL SOCIETY OF PHILADELPHIA.

(Elected January 11, 1916.)

PRESIDENT.

A. E. TAYLOR, M.D.

VICE-PRESIDENT.

HERBERT FOX, M.D.

SECRETARY-TREASURER.

O. H. PERRY PEPPER, M.D.

RECORDER.

JOHN A. KOLMER, M.D.

CURATOR.

ROBT. A. KEILTY, M.D.

MEMBERSHIP COMMITTEE.

E. A. CASE, M.D.
F. E. KEENE, M.D.
J. A. RODDY, M.D.

PUBLICATION COMMITTEE.

E. M. CASE, M.D.
A. G. ELLIS, M.D.
H. R. M. LANDIS, M.D.
E. B. KRUMBHAAR, M.D.

COMMITTEE ON MORBID GROWTHS.

GUTHRIE McCONNELL, M.D.
JOHN SPEESE, M.D.
EUGENE CASE, M.D.

BUSINESS COMMITTEE.

RICHARD M. PEARCE, M.D.
J. HAROLD AUSTIN, M.D.
H. M. FUSSEL, M.D.
W. M. L. COPLIN, M.D.

COMMITTEE ON FOUNDERS' PRIZE.

A. E. TAYLOR, M.D. (*Ex officio*)
O. H. PERRY PEPPER, M.D. (*Ex officio*)
W. M. L. COPLIN, M.D.

Digitized by Google

FORMER PRESIDENTS.

SAMUEL D. GROSS, M.D., LL.D., D.C.L. (OXON.), LL.D. (CANTAB.), elected 1857.
RENÉ LA ROCHE, M.D., elected 1858.
ALFRED STILLÉ, M.D., LL.D., elected 1859, 1861, and 1862.
EDWARD HARTSHORNE, M.D., elected 1860 and 1863.
J. M. DA COSTA, M.D., LL.D., elected 1864, 1865, and 1866.
JOHN H. PACKARD, M.D., elected 1867 and 1868.
S. WEIR MITCHELL, M.D., LL.D., elected 1869.
JOHN ASHHURST, JR., M.D., LL.D., elected 1870.
JAMES H. HUTCHINSON, M.D., elected 1871 and 1872.
WILLIAM PEPPER, M.D., LL.D., elected 1873, 1874, and 1875.
H. LENOX HODGE, M.D., elected 1876.
S. W. GROSS, M.D., elected 1879.
JAMES TYSON, M.D., elected 1882 and 1883.
E. O. SHAKESPEARE, M.D., elected 1884.
J. C. WILSON, M.D., elected 1885 and 1886.
F. P. HENRY, M.D., elected 1887 and 1888.
HENRY F. FORMAD, M.D., elected 1889 and 1890.
ARTHUR V. MEIGS, M.D., elected 1891 and 1892.
J. H. MUSSER, JR., M.D., elected 1893, 1894, 1895, and 1896.
W. E. HUGHES, M.D., elected 1897 and 1898.
F. A. PACKARD, M.D., elected 1899 and 1900.
CHARLES W. BURR, M.D., elected 1901 and 1902.
ALFRED STENGEL, M.D., elected 1903 and 1904.
W. M. L. COPLIN, M.D., elected 1905 and 1906.
JOSEPH McFARLAND, M.D., elected 1907 and 1908.
DAVID RIESMAN, M.D., elected 1909 and 1910.
ALLEN J. SMITH, M.D., elected 1912.*
RICHARD M. PEARCE, M.D., elected 1913.
DANIEL J. McCARTHY, M.D., elected 1914.
HOWARD M. FUSSELL, M.D., elected 1915.
ALONZO E. TAYLOR, M.D., elected 1916.

* Date of election changed from October to January.

Digitized by Google

Digitized by Google

LIST OF MEMBERS.

ORIGINAL MEMBERS.

JAMES DARRACH, 5923 Greene Street, Germantown.

LIFE MEMBERS.

ELECTED

1889 Anders, J. M., 1605 Walnut Street.
1887 Baker, George F., 1818 Spruce Street.
1885 Beates, Henry, Jr., 260 South Sixteenth Street.
1871 Bennett, Wm. H., 1837 Chestnut Street.
1887 Berens, Bernard, 2041 Chestnut Street.
1891 Boger, John A., 2213 N. Broad Street.
1874 Brubaker, A. P., 105 North Thirty-fourth Street.
1887 Burr, Charles W., 1918 Spruce Street.
1887 Cattell, Henry W., 3709 Spruce Street.
1872 Cohen, J. Solis, 1824 Chestnut Street.
1883 Cohen, S. Solis, 1525 Walnut Street.
1885 Daland, Judson, 317 South Eighteenth Street.
1882 Davis, G. G., 1814 Spruce Street.
1885 Deaver, J. B., 1634 Walnut Street.
1882 Dercum, F. X., 1719 Walnut Street.
1866 Duer, Edward L., 1606 Locust Street.
1876 Dulles, C. W., 4101 Walnut Street.
1891 Eshner, A. A., 1019 Spruce Street.
1881 Fenton, T. H., 1319 Spruce Street.
1876 Fisher, Henry M., 1027 Pine Street.
1885 Fussell, M. H., 2035 Walnut Street.
1882 Godey, H. E., N. E. corner Nineteenth and Spruce Streets.
1890 Grayson, C. P., 252 S. Fifteenth Street.
1883 Griffith, J. P. C., 1810 Spruce Street.
1885 Hare, H. A., Eighteenth and Spruce Streets.
1870 Henry, Frederick P., 114 S. Eighteenth Street.
1880 Hewson, Addinell, Jr., 2120 Spruce Street.
1882 Hughes, W. E., Fortieth and Chestnut Streets.
1888 Kirby, Elwood R., 1202 Spruce Street.
1869 Leaman, Henry, 828 North Broad Street.

Digitized by Google

ELECTED

1888 Leidy, Jos., Jr., 1319 Locust Street.
1875 Lewis, Morris J., 1316 Locust Street.
1886 Lloyd, James Hendrie, 116 South Twenty-first Street.
1875 Longstreth, Morris, 1416 Spruce Street.
1880 McClellan, George, 1116 Spruce Street.
1892 McFarland, J., 442 West Stafford Street, Germantown.
1878 Mills, C. K., 1909 Chestnut Street.
1884 Mitchell, J. K., 1730 Spruce Street.
1885 Morrison, W. H., 8021 Frankford Avenue, Holmesburg, Pa.
1887 Morton, S. W., 1933 Chestnut Street.
1879 Neff, J. S., Cynwyd, Montgomery Co., Pa.
1885 Piersol, George A., 4724 Chester Avenue.
1890 Potts, C. S., 2018 Chestnut Street.
1885 Randall, B. A., 1717 Locust Street.
1891 Ring, G. O., 2014 Chestnut Street.
1876 Roberts, John B., 313 South Seventeenth Street.
1890 Sartain, Paul J., 212 W. Logan Square.
1882 de Schweinitz, G. E., 1705 Walnut Street.
1881 Skillern, P. G., Jr., 241 South Thirteenth Street.
1890 Stengel, Alfred, 1728 Spruce Street.
1889 Stevens, Arthur A., 314 S. Sixteenth Street.
1884 Strittmatter, I. P., 999 North Sixth Street.
1869 Stryker, Samuel S., 3833 Walnut Street.
1863 Tyson, James, 1506 Spruce Street.
1890 Tyson, T. Mellor, 1506 Spruce Street.
1887 Westcott, T. S., 1720 Pine Street.
1869 Wilson, James C., 1509 Walnut Street.
1890 Wilson, Samuel M., 1517 Arch Street.
1890 Wood, Alfred C., 2035 Walnut Street.

MEMBERS.

1894 Abbott, A. C., 4229 Baltimore Avenue.
1907 Addison, Wm. H., School of Medicine, Univ. of Penn.
1899 Adler, L. H., Jr., 1610 Arch Street.
1910 Aiken, Thomas G., Berwyn, Pa.
1906 Allyn, Herman B., 501 South Forty-second Street.
1912 Anders, Andrews, 1708 Diamond Street.
1901 Anspach, B. M., 1827 Spruce Street.
1906 d'Apery, Tello J., 767 North Fortieth Street.
1900 Artelt, H., 1521 North Eighth Street.
1889 Ashton, William E., 2011 Walnut Street.
1909 Austin, James H., Ardmore, Pa.
1913 Axilbund, Samuel, 5802 Cedar Avenue.

Digitized by Google

ELECTED

1897 Babcock, W. Wayne, 2033 Walnut Street.
1914 Baer, B. F., Jr., 2039 Chestnut Street.
1911 Bauer, Marie L., 1613 Fairmount Avenue.
1906 Beardsley, E. J. G., 2030 Chestnut Street.
1900 Behrend, Moses, 1427 North Broad Street.
1900 Bergey, D. H., 206 South Fifty-third Street.
1905 Bernheim, Albert, 1225 Spruce Street.
1908 Bethel, John P., 1825 Fairmount Avenue.
1913 Birdsall, Jos. C., 3459 Chestnut Street.
1905 Blackwood, J. D., Jr., 5346 Wayne Avenue, Germantown.
1905 Bland, P. B., 1621 Spruce Street.
1914 Block, Frank B., 1503 Girard Avenue.
1908 Boice, J. Morton, 4020 Spruce Street.
1912 Bonney, Charles W., 1117 Spruce Street.
1893 Boyer, H. P., 4602 Baltimore Avenue.
1898 Brinton, Ward, 1423 Spruce Street.
1912 Brown, Claude P., Glenolden, Pa.
1896 Brown, H. MacV., 4608 Baltimore Avenue.
1916 Brown, Henry, Jr., 1523 Locust Street.
1893 Bryan, J. Roberts, 4200 Chestnut Street.
1908 Busch, John Williams, 2500 South Eighteenth Street.

1907 Cadwalader, W. B., 1710 Locust Street.
1902 Carnett, J. B., 123 South Twentieth Street.
1901 Carpenter, H. C., 1805 Spruce Street.
1914 Carrington, W. J., 905 Pacific Avenue, Atlantic City, N. J.
1913 Casselman, Arthur J., 317 Penn Street, Camden, N. J.
1898 Chestnut, J. C., 1817 Frankford Avenue.
1899 Clark, John G., 2017 Walnut Street.
1907 Cohen, A. J., 723 Pine Street.
1902 Cohen, M. Solis, 4102 Girard Avenue.
1896 Coley, Thomas Luther, Bethayres, Pa. Box 32.
1907 Conaway, W. P., 1723 Pacific Avenue, Atlantic City, N. J.
1905 Cope, Thomas A., 6504 Germantown Avenue.
1890 Coplin, W. M. L., 606 South Forty-eighth Street.
1900 Craig, F. A., 244 South Twenty-first Street.
1898 Cruice, John M., 1932 Spruce Street.
1901 Cryer, M. H., 140 South Lansdowne Avenue.
1898 Currie, Thos. R., 512 W. Lehigh Ave.

1896 Da Costa, J. C., Jr., 264 South Fifteenth Street.
1894 Da Costa, J. Chalmers, 2045 Walnut Street.
1909 Davis, A. B., 511 Cooper Street, Camden, N. J.
1893 Davisson, Alex. H., Ardmore, Pa.
1889 Deaver, H. C., 1534 North Fifteenth Street.
1904 Dever, Francis J., 319 South Eighteenth Street.

Digitized by Google

ELECTED

1913 Dewees, A. L., Haverford, Pa.
1907 Dintenfass, H., 415 Pine Street.
1910 Donaldson, H. H., Wistar Institute, 37th St. and Woodland Av.
1901 Dorrance, G. M., 2025 Walnut Street.
1913 Dorworth, Charles V., 1520 Erie Avenue.

1902 Ellis, A. G., Jefferson Medical College.
1900 Erck, T. A., 251 South Thirteenth Street.
1914 Estes, W. L., South Bethlehem, Pa.

1901 Farr, C. B., 117 South Twenty-second Street.
1907 Fetterolf, George, 134 South Twentieth Street.
1902 Fife, C. A., 2033 Locust Street.
1907 Flick, Lawrence F., 738 Pine Street.
1902 Fox, H., Pepper Laboratory, Univ. of Penna.
1893 Fox, L. Webster, 1636 Spruce Street.
1899 Francine, A. P., 264 South Twenty-first Street.
1895 Frazier, Charles Harrison, 1724 Spruce Street.
1914 Fretz, J. E., Easton, Pa.
1913 Funk, E. D., Jefferson Hospital.
1910 Funk, Elmer H., 1318 Spruce Street.

1902 Geisler, Howard D., 35 High Street, Germantown.
1916 Gerhard, Arthur, 2110 Pine Street.
1901 Gildersleeve, Nathaniel, Laboratory of Hygiene, Univ. of Penna.
1901 Gilliland, S. H., Widener Building.
1908 Ginsburg, Nathaniel, 1704 Pine Street.
1894 Girvin, John H., 2120 Walnut Street.
1904 Goldberg, H. G., 1925 Chestnut Street.
1909 Goldsmith, S. Byron, 247 South Thirteenth Street.
1906 Goodman, E. H., 248 South Twenty-first Street.
1905 Gordon, Alfred, 1812 Spruce Street.
1910 Gray, Clarence H., 2044 Chestnut Street.
1912 Greene, E. M., 222 Spring Garden Street, Easton, Pa.
1906 Guilfoyle, W. F., 4108 Baltimore Avenue.
1890 Gummey, Frank B., 5418 Greene Street, Germantown.
1900 Gwyn, N. B., 20 South Twenty-first Street.

1893 Hamill, S. M., 1822 Spruce Street.
1909 Hammond, L. J., 1222 Spruce Street.
1893 Hand, Alfred, Jr., 1724 Pine Street.
1910 Hartz, Harry J., 1002 Jackson Street.
1890 Hartzell, M. B., 3644 Chestnut Street.
1904 Hatfield, C. J., 2008 Walnut Street.
1912 Hawk, Philip B., Jefferson Medical College.

Digitized by Google

ELECTED

1900 Head, J., 1500 Locust Street.
1896 Henry, J. Norman, 1906 Spruce Street.
1916 Herman, J. Leon, 1701 Chestnut Street.
1903 Hill, H. K., 314 South Seventeenth Street.
1899 Hitchens, A. P., Glenolden, Pa.
1899 Holloway, T. B., 1819 Chestnut Street.
1905 Holmes, E. B., 219 South Forty-first Street.
1909 Hopkins, A. H., 1804 Pine Street.
1904 Hoyt, D. M., 3604 Chestnut Street.
1904 Hume, J. E., 900 South Forty-ninth Street.
1902 Hunter, John W., 2042 Pine Street.

1911 Jonas, Leon, 2253 North Seventeenth Street.
1895 Jopson, J. H., 1824 Pine Street.
1898 Judson, Chas. F., 1005 Spruce Street.
1899 Jump, H. D., S. E. cor. Forty-seventh and Chester Avenue.

1914 Kalteyer, F. J., 1533 Pine Street.
1901 Kane, Bayard, Fern Hill Farm, West Chester, Pa.
1912 Keating, P. McCall, Wawa, Pa.
1906 Keene, Floyd E., 116 South Nineteenth Street.
1910 Keilty, Robert A., 95 East Essex Avenue, Lansdowne, Pa.
1906 Kelly, James A., 1510 North Seventeenth Street.
1905 Kelly, Thos. C., 105 Schoolhouse Lane, Germantown.
1899 Kennedy, L. F., 301 Mauch Chunk Street, Pottsville, Pa.
1914 Kite, G. L., Henry Phipps Institute, Philadelphia.
1916 Klauder, Jos. V., 1514 West Tioga Street.
1898 Knipe, J. C., 2035 Chestnut Street.
1901 Kohn, B., 1516 North Fifteenth Street.
1910 Kolmer, John A., Medical Laboratory, University of Pennsylvania.
1908 Kotz, Adam L., Easton, Pa.
1908 Krumbhaar, Ed. B., Mermaid Lane, St. Martin's.

1909 Laird, John, Reading, Pa.
1899 Landis, H. R. M., 11 South Twenty-first Street.
1890 Laplace, Ernest, 1828 South Rittenhouse Square.
1914 Laws, G. M., 2033 Locust Street.
1904 Leopold, Samuel, 318 South Fifteenth Street.
1916 Leopold, Simon, 1428 North Broad Street.
1910 Lewis, Paul A., 4339 Pine Street.
1898 Lodholtz, Edward, 3103 Diamond Street.
1894 Loeb, Ludwig, 1421 North Fifteenth Street.
1903 Ludlum, S. D., Gladwyn, Pa.
1903 Lukens, G. T., East Fifth Street, Conshohocken, Pa.
1915 Lynch, Frank B., Jr., 5413 Sansom Street.

Digitized by Google

ELECTED

1911 Lyon, Vincent, 1828 Pine Street.

1896 McCarthy, D. J., 2025 Walnut Street.
1912 McCrae, Thomas, 1627 Spruce Street.
1893 McKee, James H., 1402 Spruce Street.
1911 MacPhail, Margaretta, Harrisburg, Pa.
1905 Maier, E. G., 1323 North Fifteenth Street.
1905 Maier, F. Hurst, 2035 Chestnut Street.
1902 Marshall, C. J., 5031 Pine Street.
1914 Martin, S. P., Buffalo, N. Y.
1910 Meyer, K. F., San Francisco, Cal.
1905 Meyers, Milton K., 1529 South Broad Street.
1914 Miller, T. G., 1805 Pine Street.
1907 Montgomery, C. M., 2210 Locust Street.
1899 Müller, G. P., 1729 Pine Street.
1909 Musser, John H., Jr., 121 South Twentieth Street.

1913 Narr, Frederick C., 1636 South Eighteenth Street.
1911 Nathan, David, Norristown.
1900 Newlin, A., 1804 Pine Street.
1898 Newton, R. D., 6137 Vine Street.
1910 Nicholson, W. R., 1731 Pine Street.
1901 Norris, Charles C., 1503 Locust Street.
1900 Norris, Geo. W., 1530 Locust Street.
1910 Nylin, Josef L., 1611 Walnut Street.

1894 O'Malley, Joseph, 2228 South Broad Street.
1911 Outerbridge, George W., 2039 Chestnut Street.

1892 Packard, F. R., 302 South Nineteenth Street.
1907 Pancoast, H. K., Box 203, Bala, Pa.
1910 Pearce, Richard M., 2114 DeLancey Street.
1913 Peet, Max M., Ann Arbor, Mich.
1903 Pemberton, R., 2224 Locust Street.
1911 Pennington, Mary, 1833 Chestnut Street.
1910 Pepper, O. H. Perry, 1811 Spruce Street.
1897 Pepper, William, 1811 Spruce Street.
1916 Petty, O. H., 6215 Ridge Avenue.
1902 Pfahler, G. E., 1321 Spruce Street.
1909 Pfeiffer, Damon B., 2028 Pine Street.
1905 Piersol, Geo. M., 1913 Spruce Street.

1905 Rahte, Walter E., Aldine Hotel.
1912 Randall, Alexander, 1831 Chestnut Street.
1904 Reber, Wendell, 1212 Spruce Street.

Digitized by Google

ELECTED

1893 Reckefus, C. H., Jr., 506 North Sixth Street.
1910 Rees, W. T., 3763 North Eighteenth Street.
1914 Reeves, R. S., 1916 Spruce Street.
1906 Reichel, John, Glenolden, Pennsylvania.
1907 Repplier, S. J., 4521 Chester Avenue.
1899 Reynolds, Walter, 27 South Indiana Ave., Atlantic City, N. J.
1894 Rhein, J. H. W., 1732 Pine Street.
1902 Rhein, R. D., Fifteenth and Pine Streets.
1910 Richards, A. N., University of Pennsylvania.
1912 Richardson, Russell, Newtown, Pa.
1893 Riesman, David, 1715 Spruce Street.
1911 Ringer, A. I., 12 Mt. Morris Park, New York.
1904 Rivas, Damaso, 106 East Plumstead Avenue, Lansdowne, Pa.
1894 Robertson, W. E., 327 South Seventeenth Street.
1901 Robinson, E. T., 1906 Pine Street.
1889 Robinson, William Duffield, 2012 Mount Vernon Street.
1911 Roddy, J. A., Jr., 1604 Pine Street.
1899 Rosenberger, R. C., 2330 North Thirteenth Street.
1893 Ross, G. George, 1721 Spruce Street.
1911 Rucker, J. B., Jr., Lansdowne, Pennsylvania.

1895 Sailer, Joseph, 1718 Spruce Street.
1913 Sappington, S. W., 124 South Sixteenth Street.
1904 Sargent, A. Alonzo, 1308 Pine Street.
1912 Saxon, G. J., 5314 Spruce Street.
1909 Schaffle, Karl, State Department of Health, Harrisburg, Pa.
1895 Schamberg, J. F., 1922 Spruce Street.
1914 Schnabell, T. G., 1805 Pine Street.
1904 Schumann, E. A., 15 Pelham Road, Germantown.
1902 Shields, W. G., Jr., 414 Schoolhouse Lane, Germantown.
1889 Shoemaker, Harvey, 2011 Chestnut Street.
1899 Sinclair, J. F., 4103 Walnut Street.
1902 Sinkler, Francis W., 1606 Walnut Street.
1901 Siter, E. H., 1818 South Rittenhouse Square.
1910 Skillern, P. G., Jr., 241 South Thirteenth Street.
1903 Small, J. H., 914 South Forty-eighth Street.
1903 Smith, A. J., Medical Department, University of Pennsylvania.
1897 Smyth, Henry Field, 217 Walnut Street, Wayne, Pa.
1902 Somers, Lewis S., 3554 North Broad Street.
1906 Sommers, Henry J., Blair County Hospital for Insane, Hollidaysburg, Pa.
1905 Speese, John, 2206 Locust Street.
1893 Spellissy, Joseph M., 317 South Fifteenth Street.
1904 St. John, E. Q., 2201 Chestnut Street.
1890 Stahl, B. F., 1727 Pine Street.
1904 Stellwagen, Thomas C., Jr., 1831 Chestnut Street.

Digitized by Google

ELECTED

1905 Stout, Philip S., 4701 Chester Avenue.
1912 Swalm, Charles J., 134 E. 4th Avenue, Conshohocken, Pa.
1894 Swan, John M., 457 Park Avenue, Rochester, N. Y.
1916 Sylvis, Wm. M., 1903 South Broad Street.

1899 Talley, J. E., 218 South Twentieth Street.
1910 Taylor, A. E., New Medical Laboratory, Univ. of Penna.
1897 Teller, Wm. H., 1713 Green Street.
1906 Thomas, B. A., 116 South Nineteenth Street.
1894 Thomas, W. Hersey, 1445 North Seventeenth Street.
1902 Thornton, E. Q., 1331 Pine Street.
1909 Torrey, Robert G., 1716 Locust Street.
1902 Tracy, S. E., 1527 Spruce Street.
1897 Tucker, Henry, 2000 Pine Street.

1913 Valentine, Edna S., 2231 North Nineteenth Street.
1909 Van Gasken, Frances C., 115 South Twenty-second Street.
1909 Vaux, Norris Wister, 8901 Germantown Avenue, Chestnut Hill.

1809 Walsh, J., 2026 Chestnut Street.
1910 Weidman, Fred D., 242 North Sixty-first Street.
1903 Weisenburg, T. H., 1909 Chestnut Street.
1913 Whaland, Berta, 2335 West Berks Street.
1897 White, Courtland Y., 1808 Diamond Street.
1911 White, Ellen P. Corson, 31 Main Street, Norristown, Pa.
1892 Whiting, A. D., 1523 Spruce Street.
1910 Willard, De Forest P., 1933 Chestnut Street.
1910 Williams, P. F., 121 South Twentieth Street.
1912 Wilmer, H. B., 138 West Walnut Lane, Germantown.
1914 Wilson, G., 5000 Walnut Street.
1910 Wise, Henry M., 1640 Erie Avenue.
1898 Wood, George B., 129 South Eighteenth Street.
1899 Worden, C. B., 322 South Sixteenth Street.

1911 Young, Charles H., 4813 Baltimore Avenue.

1902 Zimlick, A. J., Green and Harvey Streets, Germantown.

Digitized by Google

NON-RESIDENT MEMBERS.

SUBSCRIBERS TO THE PROCEEDINGS.

Biggs, M. H., Rutherfordton, N. C.
Cummins, W. T., Southern Pacific Hospital, San Francisco, Cal.
Dock, George, Washington University, Locust and Eighteenth Streets, St. Louis, Missouri.
Eisenbrey, A. B., St. Luke's Hospital, New York.
L'Engle, Edward M., L'Engle Building, Jacksonville, Fla.
Foster, G. B., Fort Leavenworth, Kansas.
Hamann, C. A., 404 Osborn Building, Cleveland, Ohio.
Hawke, N. W., Clifton Heights, Delaware County.
Hunt, C. J., Department of Health, Harrisburg, Pa.
Ivy, R. H., First National Bank Building, Milwaukee, Wis.
McConnell, Guthrie, Waterloo, Iowa.
Potter, F. C., Central Indiana Hospital, Indianapolis, Ind.
Rahter, C. A., 110 North Second Street, Harrisburg, Pa.
Ravenel, M. P., University of Wisconsin, Madison, Wis.
Royer, B. Franklin, Donaldson Bldg., Harrisburg, Pa.
Wood, Harold B., Rochester, Minn.

NON-RESIDENTS NOT SUBSCRIBERS.

Alburger, Henry R., Bloomington, Indiana.
Ayer, Ira, Pasteur Institute, Bangkok, Siam.
Ball, M. V., Warren, Pa.
Barnes, A. S., Jr., Missouri Trust Building, St. Louis, Mo.
Cadbury, W. W., University Medical School, Canton, China.
Carter, W. S., University of Texas, Galveston, Texas.
Coca, A. F., Cornell Medical College, New York.
Cooke, Jean V., University of California, Berkeley, Cal.
Edsall, David L., Harvard Medical School, Cambridge, Mass.
Edwards, W. A., 610 Braley Bldg., Los Angeles, Cal.
Evans, Joseph S., Madison, Wis.
Gaylord, H. R., 472 Delaware Ave., Buffalo, N. Y.
Gerson, T. P., 1621 Ingraham Street, Los Angeles, Cal.
Hamaker, W. D., Meadville, Pa.
Harris, H. F., Atlanta Coll. of Phys. and Surg., Atlanta, Ga.
Harrison, W. H., 43 McCartney St., Harrisburg, Pa.

Digitized by Google

Hatch, John L., 913 Seventh Avenue, New York City.
Hickman, W. A., 612 Pacific Avenue, Atlantic City, N. J.
Holder, C. A., Colorado Springs, Col.
Howard, F. H., Williams College, Williamstown, Massachusetts.
Hunt, J. R., 102 East Fifty-seventh Street, New York City.
Jamar, John H., Elkton, Cecil Co., Md.
Karsner, H. T., Harvard Medical School, Cambridge, Mass.
Kiefer, Charles, United States Army.
Kinyoun, J. J., 1423 Clifton St., Washington, D. C.
Lincoln, W. R., Coll. of Phys. and Surg., Cleveland, Ohio.
Loeb, Leo., Barnard Skin and Cancer Hospital, St. Louis, Mo.
de Nancrède, C. B. G., Ann Arbor, Mich.
Pease, H. D., 116 Washington Ave., Albany, N. Y.
Potter, F. C., Central Indiana Hospital for Insane, Indianapolis, Ind.
Powell, W. M., 122 West Minor Street, West Chester, Pa.
Robinson, G. Canby, Rockefeller Research Hospital, New York City.
Slifer, Henry F., North Wales, Mont. Co., Pa.
Stadelman, Eugene, "Magistral," Maria Del Oro, Mexico.
Sutter, C. Clyde, 275 Alexander Street, Rochester, N. Y.
Taylor, L. H., 8 South Franklin St., Wilkesbarre, Pa.
Toulmin, H., Haverford, Pa.
Wells, G. M., Wayne, Delaware County, Pa.
Weston, P. G., Warren, Pa.
Wetherill, R. B., Lafayette, Ind.
Williams, H. L., 327 Fourteenth Ave., S. E., Minneapolis, Minn.
Wilmarth, A. W., State Home for the Feeble-minded, Chippewa Falls, Wisconsin.
Wilson, J. D., 210 Connell Building, Scranton, Pa.
Wohl, Michael G., Omaha, Neb.

CORRESPONDING MEMBERS.

ELECTED

1885 Dent, Clinton T., St. George's Hospital, London, England.
1888 Fideli, Gregorio, Rome, Italy.
1908 Flexner, Simon, Rockefeller Institute, New York City.
1908 Novy, F. G., Ann Arbor, Michigan.
1908 Osler, Sir William, University of Oxford, Oxford, England.
1886 Pye-Smith, P. H., Guy's Hospital, London, England.
1898 Welch, William H., Johns Hopkins University, Baltimore, Md.

Digitized by Google

PROCEEDINGS

OF THE

Pathological Society of Philadelphia.

Some Lessons of the War on the High Cost and High Plane of Living.[1]

ALONZO E. TAYLOR, M.D.

January 11, 1917.

Fragmentation of the Ovum Within the Graafian Follicle.

WILLIAM H. F. ADDISON, M.B.

(From the Anatomical Laboratory, University of Pennsylvania.)

Lantern slides of photomicrographs of ovaries of mature and immature albino rats were shown, to illustrate a phenomenon which has been observed in a number of mammals, and which has been variously interpreted. In certain of the Graafian follicles, instead of a single oöcyte, are seen a group of cell-like, rounded structures which have evidently arisen from the one-egg cell. In the illustration shown, one had seven and the other eight such cell-like bodies. The question is, whether these cells have arisen parthenogenetically by cleavage divisions or by an irregular process of separation of the cytoplasm and nucleus into a number of parts. From the fact that definite nuclei were not seen in most of the cell-like bodies a tentative opinion was expressed that the phenomenon was one of degeneration. This is contrary to the conclusions of Leo Loeb, who has described more advanced stages of ovarian parthenogenetic development in guinea-pigs (*Biol. Bull.*, 1915), but is in accord with those of H. M. Kingery in young white mice (*Biol. Bull.*, 1914). *January* 27, 1916.

[1] Title of the Address of the retiring President.

Digitized by Google

Aberrant Cerebellar Tissue in Occipital Bone.

FRED D. WEIDMAN, M.D.

About ten pits were found in the right occipital bone, 2 to 8 mm. in diameter, running in a line immediately below and parallel to the lower border of the lateral sinus. The largest extended almost through the bone to soft tissues and contained an 8 mm. diameter mass of tissue showing characteristic microscopic features of the cerebellum. The adjacent cerebellum proper showed a shallow depression, but a connection between it and the ectopic tissue could not be presumed on account of removal of brain before its discovery. There was no fibrosis or blood pigmentation to indicate preëxistent traumatic or other mechanical factor in causation. The writer believes the ectopia to be developmental, cerebellar "anlagal" cells having been snared off and carried by developing mesoderm into a new position. From the regular position of the pits containing the nervous tissue they must be Pacchionian depressions and the ensnaring mesodermic tissue was most likely, therefore, undifferentiated Pacchionian bodies. In order to have produced such a large pit in early life (they normally grow large only in late years), accommodative for such a notable portion of cerrebellum the Pacchionian bodies must have been stimulated to unusual erosive activity. *January* 27, 1916.

Accessory Pancreases (Two) in Wall of Jejunum.

FRED D. WEIDMAN, M.D.

Fifty cm. below the duodenojejunal junction the jejunal wall bore, at its attached border, a 4 x 3 x 1 cm. thickening, and beyond this a second of about half this size. The wall here was thickened to the extent of 1 cm., mucosa thinned but not ulcerated, finely nodular and showing no ducts grossly. On section, lobulation is noted, comparable in size to pancreatic ones, but more irregular in shape, some pale gray and translucent, others opaque and yellowish gray. Microscopically, the tissue occupies mainly the submucosa and muscularis, shows acini and islets of Langerhans in proper lobules, between which there are numerous distended, highly adenomatous ducts. The general trend is toward the jejunal mucosa, upon which they probably from this opened, although actual exit was not shown in sections examined. Causation along the same lines (developmental) as indicated in the above cerebellar case. (See paper by author in *Anatomical Record*, April, 1913, vol. 7, No. 4.) *January* 27, 1916.

Digitized by Google

Massive Hemorrhage of Adrenal in Adult, Aged Sixty-four Years.

FRED D. WEIDMAN, M.D.

Unfortunately, the history notes on this case are very brief and refer only to the bronchopneumonia diagnosed clinically. In a case with such extensive, autopsy-proven, acute adrenal destruction the history would have been of great value, particularly when we are only on the threshold of symptom-complexes of the endocrinous system. The lungs showed a central bronchopneumonia at autopsy, general arteriosclerosis, and the special adrenal lesion. The left one was of about normal size, its medulla solid, dark brown, and containing fine brown islands of tissue suggesting islands of parenchyma in a diffuse hemorrhage. The right adrenal was very large, measuring 7 x 4 x 7.5 cm., showing a very thin yellow cortex and firm, dark red, almost black medulla. Microscopically, a diffuse hemorrhage was found with extensive necrosis and but a small portion of the cortex remaining vital. Veins showed thrombosis and mural necrosis; arteries show sclerosis. Presumably this is a massive hemorrhagic infarct coming about from septic thrombosis of medullary veins, just as such infarction results from occluding lesions of the splenic vein. These hemorrhages, common in the very young, are rare in the aged. *January* 27, 1916.

Retrograde Venous Metastasis by Hypernephroma to Iliac Veins and Lumbar Vertebræ.

FRED D. WEIDMAN, M.D.

The special features of this case consisted not in the size of the primary lesion nor the metastasis which solidly filled the renal vein and partially the inferior cava. These are common. In this case a metastatic focus was found upon the lining of the cava just above its bifurcation, others in and solidly occupying two lumbar veins, right and left, and a very large one in the second, third and fourth lumbar vertebræ, eroding thence into the left iliac vein about 4 cm. from the cava. The rationale supposed is one of retrograde venous embolism from the higher caval tumor, depending upon some dyspneic paroxysm giving stoppage or reflux of caval blood, during which cells drop or are carried in a backward direction to the retrograde position. From this point the tumor extended *via* lumbar veins into the vertebræ, eventually eroding the left iliac vein. The intervertebral disks were far less destroyed than their osseous neighbors. (Cf. erosion of aneurysm.)

January 27, 1916.

Digitized by Google

Pontine Hemorrhage in a Subject, Aged Twenty-eight Years.

FRED D. WEIDMAN, M.D.

The subject had an alcoholic history; died when in hospital but a few hours. At autopsy the pons fluctuated, and upon incision revealed a fresh hemorrhage 30 x 25 mm., the ring of pontine substance around it measuring from 1 to 10 mm. in thickness, but being nowhere ruptured to permit extravasation into meninges. The cerebral vessels were heavily beaded by arteriosclerosis, some of them atheromatous. The renal arterioles were also sclerotic, giving organs weighing 100 and 120 grams. Heart weighed 500 grams, its valvular orifices and aorta itself clearly hypoplastic. No signs of syphilis, grossly or microscopically. Hemorrhage at this early age is explained primarily by her alcoholic habits and hypoplastic cardiovascular system. Both of these conspired toward her cardiac hypertrophy, and the combination to the marked chronic diffuse nephritis found. There was now every reason for high blood-pressure, this and the vascular weakness finally giving the fatal issue. *January* 27, 1916.

Death at the Age of Twenty-two from Mesenteric Thrombosis, the Result of Arteriosclerosis with Terminal Peritonitis.

FRED D. WEIDMAN, M.D., AND RICHARD A. KERN, M.D.

The unusual features of this case were the extreme grade of cardiovasculorenal lesions and the production of death thereby so early in life.

The patient had a "touch of diphtheria" at the age of eight years and numerous attacks of tonsillitis in childhood, and was told she had "kidney trouble" from childhood. Severe toxemias during two pregnancies, the first miscarried, the second terminated surgically. Later was admitted to hospital with uremia, where she suddenly developed signs of peritonitis and died.

Autopsy showed diffuse suppurative peritonitis and fecal discharge through several perforations of small intestines. The microscope showed extensive hyaline endarteritis and thrombosis of the small arterioles of the intestinal submucosa, numerous small hemorrhages and foci of blood pigment, and ulceration and necrosis of portions of the mucosa. Heart enormously hypertrophied, kidneys of advanced arteriosclerotic type, the one, in addition, hypoplastic.

Death was clearly due to peritonitis secondary to the perforation. The perforation was due to necrosis of the gut wall secondary to hemorrhagic infarction, and the infarction resulted from thrombosis in the sclerosed mesenteric vessels.

Digitized by Google

The arteriosclerosis so early in life is hard to explain, but was probably secondary to renal disease, the latter induced by her recurrent pharyngeal infections. Her pregnancies probably assisted.

January 27, 1916.

Hyperplastic Bone Formation under Old Mammary Operative Site.

FRED D. WEIDMAN, M.D.

From autopsy upon black female, aged forty-seven years, dying of diabetes. Lesion sprang from whole width of third rib, downward, parallel to thoracic cage, ending over middle of fourth rib. It measured 35 mm. long and 13 mm. at base, tapering to 13 mm. at tip and was of subcylindrical form, slightly bent in middle. Surface smooth, covered by periosteum, especially thick at tip. No foreign bodies (sutures) in relation to it. The specimen is presented to show that bony outgrowths should be numbered along with the secondary lesions to be found in the breast of an old woman, and thought of clinically when considering such a case. As to the etiology, it doubtless would have been considered an osteoma, if occurring on the other side of this woman or in a male; but with the history of earlier possible trauma (surgical operation) an irritative factor must be granted and the lesion regarded as of hyperplastic nature. *January* 27, 1916.

Unusual Amyloid Kidney.

BALDWIN LUCKE, M.D.

Specimen from a West Indian seaman, aged twenty-three years, admitted on the service of Dr. Stevens at Blockley. He gives a history of lues, and has spent practically his entire life in tropics.

On admission he presented the picture of general edema. Wassermann reaction was positive.

At autopsy several liters of milky fluid were found in the abdomen and pleural cavity. This fluid gave a chemical reaction for sugar and fat. Filariæ were suspected but were not demonstrated.

Kidneys are both very large, right weighing 520, left 430 grams. Organs of a pale yellowish-brown color, have smooth surface, and are increased in consistency. Cut surface is of same pale color. Cortex measures on average 2 cm., and shows fine yellowish granularities irregularly distributed. Edges of cut surface gape slightly.

Microscopic Examination. Amyloid kidney with parenchymatous degeneration. *January* 27, 1916.

Digitized by Google

Nephrolithiasis of a Cow.

BALDWIN LUCKE, M.D.

The stone is the size of a walnut, of grayish color, and has an irregular surface. It is very firm in consistency, and occupies a fibrous bed in the pelvis of the kidney. *January* 27, 1916.

Cholesteatoma Basis Cerebri.

B. H. LUCKE, M.D. AND R. H. LANDON, M.D.

White female, aged nineteen years, from Dr. Frazier's service of the Hospital of the University of Pennsylvania, admitted September 24, 1915. Complains of failing vision and headache. These symptoms have persisted for the past eighteen months. Headache is most severe from right eye and temporal region. It begins in the morning and lasts until noon. One year ago patient lost sight in right eye and also complains of increased frequency in micturition. There is no nutritional disturbance and nothing of note in family or previous history.

On examination, body is that of a well-nourished girl which showed no notable visceral disturbances. Nervous examination was negative. Blood, urine, temperature, pulse, and respiration normal.

Eye Examination. No difference in prominence of globes of the eye. Left pupil reacted to light and accommodation; right to accommodation only. Both optic disks showed advanced atrophy. Retinal vessels were reduced in size. *X*-ray showed growth in the region of the sella turcica.

On September 25 Dr. Landon performed a transsphenoidal hypophysotomy, removing some friable mass. Two days later the patient developed a temperature, became acutely ill, and died on September 29.

Autopsy showed plastic meningeal exudate. In the region of the pituitary body is seen an irregular growth the size of a large walnut, extending anteriorly to beyond the optic commissure, posteriorly to the pons, laterally to the overhanging lobes of the temple. Transverse incision showed it to be superficial, lying upon the pia arachnoid, pushing in but not infiltrating the brain substance. Tumor is pearly gray in color, consists of many nodules, which are hard and brittle, and whose cut surface has a mother-of-pearl or silky sheen.

Microscopic examination shows rows of endothelial cells, poor in nuclei, and apparently undergoing necrosis. Here and there, especially in fresh, unstained specimens, flat polyhedral cells can

Digitized by Google

be seen, in and between which are typical crystals of cholestrin. Chemical tests gave the usual reactions for cholestrin. Cultures from lateral ventricles showed Staphylococcus aureus.

January 27, 1916.

Chondroma of the Pelvis.

B. H. LUCKE, M.D. AND JOSEPH MCIVER, M.D.

Patient was a white male, aged sixty-three years; admitted to the service of Dr. Musser in the Philadelphia General Hospital June 5, 1915. He complained of swelling of the right leg, which began about nine months before admission. About ten months before admission he noticed a hard, large mass in the right lower abdomen. On examination he was somewhat emaciated, with a distended abdomen.

In the right iliac fossa there is a mass, firm to touch, springing, apparently, from the symphysis pubis and occupying the entire iliac fossa, extending as high as the umbilicus. *X*-ray did not show a shadow of this tumor. Patient died some time later with an acute intercurrent infection.

At autopsy a roundish mass the size of a man's head was found to spring from the symphysis, pressing upon the iliac vein and cecum. Tumor is of a grayish color and firm consistency, and it is somewhat nodular. Cut surface shows numerous thick fibrous bands dividing it into further nodules. In places there is a jelly-like softening.

Under the microscope the tumor consists of a tissue resembling hyaline cartilage. *January* 27, 1916.

Syphilis and Tuberculosis in the Same Lung.[1]

ROBERT A. KEILTY, M.D.

In the summary of this case the following interesting facts are presented: A colored male, aged twenty-three years, shows a progressive loss of weight, with cough, dyspnea, and a profuse fetid expectoration of three weeks' duration (seven weeks before death). The physical signs point to infiltration and cavity in the lower left lung, with infiltration in the right. In the absence of tubercle bacilli in the sputum and with a history of a rapid course a diagnosis of pulmonary gangrene led to operation, when the tuberculous nature of the case was revealed.

[1] Published in the New York Medical Journal, August 5, 1916.

Digitized by Google

At death autopsy demonstrated the left lung to be the seat of a cylindrical dilatation of the bronchi, with two fairly large bronchiectatic cavities and a generalized overgrowth of fibrous tissue. Presumably engrafted upon this, or possibly primarily present and secondarily stimulated by the syphilitic process, a tuberculous process of miliary and conglomerate tubercles with caseation was present. Microscopically, some of the tubercles closely resembled gummata. The tubercle bacillus and the Spirocheta pallida were demonstrable in appropriately stained preparations.

January 27, 1916.

Hydrocephalus the Result of Cyst of the Cerebellum.

ROBERT A. KEILTY, M.D.

This is a case of glioma of the cerebellum with a large cystic degeneration involving the fourth ventricle. Pressure by this cyst upon the foramen of Majendi has resulted in dilatation of the lateral ventricles with the production of an internal hydrocephalus. I am indebted to Drs. Spiller and Griffith for permission to use the case.

January 27, 1916.

Fibro-adenorhabdomyomatous Mesothelioma of the Kidney.

ROBERT A. KEILTY, M.D.

(From the McManes Laboratory of Pathology, University of Pennsylvania.)

I am indebted to Dr. George H. Denney for the privilege of reporting this case. The patient was a male child, aged three years. Complained of extreme shortness of breath, a mechanical interference with respiration. The urinary findings were unworthy of note. Growth increased rapidly in size over the last eight months of life. At an exploratory operation it was not deemed advisable to remove the tumor.

At autopsy the tumor consisted of two parts: one the middle portion of the left kidney and the other a larger spherical mass attached to the kidney portion by a pedicle. The mass weighed 1150 gm. and measured 23 cm. in diameter. Microscopically, the kidney portion is made up of two types of cells without much framework, an embryonic stellate cell and a closely packed vesicular nucleated round cell. The larger mass has a loose fibrous capsule, a loose embryonic connective tissue, contains islands of cells, fatty connective tissue, poorly defined tubules, and glomerules and fine strands of voluntary muscle. The tumor was limited to the left kidney region, was sharply defined, and gave no metastases.

January 27, 1916.

Digitized by Google

Hydrochloric Acid as a Decolorizing Agent for the Tubercle Bacillus.

ROBERT A. KEILTY, M.D.

(From the McManes Laboratory of Pathology, University of Pennsylvania.)

The use of hydrochloric acid is not generally advocated as a decolorizer for acid-fast organisms. I have used it in a watery solution of 30 per cent. for two years, including blood, smears, sputum, sections, and cultures. It should remain on thin smears for at least thirty seconds to one minute by watch. Smears were made from a fresh culture of the tubercle bacillus, an old culture, and sputum. These were stained with cold carbol-fuchsin five minutes. Hydrochloric acid was allowed to remain on the slides one minute, two minutes, and so on up to ten minutes, then fifteen, twenty, twenty-five, and thirty minutes. It was found with variations that all retained their acid-fast properties even for thirty minutes. Fading starts at about five minutes. The old culture was more retentive than the fresh one or the sputum.

The technic used was as follows: Thin smears on glass slides; fix in heat; stain cold carbol-fuchsin five minutes; decolorize hydrochloric acid (30 per cent.) thirty seconds to one minute; counterstain with Löffler's methylene blue. All artefacts are completely decolorized. *January* 27, 1916.

A Cardiac Formula for the Relative Measurements of the Valvular Orifices.[1]

ROBERT A. KEILTY, M.D.

The purpose of this presentation is to offer a working basis for the determination of cardiac valvular stenosis or insufficiency. In an autopsy technic the incisions for opening the heart vary to a wide extent, each individual operator having a method of choice. I am in the habit of opening the left ventricle first, exposing the aortic and mitral in order, then the right ventricle, exposing the tricuspid and pulmonary orifices. Thus aortic, mitral, tricuspid, and pulmonary may be examined in order. In this paper these openings are designated A-M-T-P.

The measurements were always confusing to me until a few years ago I noticed the following ratio was almost a constant factor: A 7, M 9, T 11, P 7, 7-9-11-7. These are the only figures one needs to remember. These vary within the normal to 9-11-13-9.

[1] Published in Journal of Laboratory and Clinical Medicine, 1916, vol. i, No. 7.

Digitized by Google

CONCLUSIONS. 1. In the following order, A-M-T-P, a cardiac valvular formula in centimeters, 7-9-11-7, may be used as a practical working basis for the determination of stenosis or insufficiency.

2. This varies in accordance with the size of the heart within these limits, 7-9, 9-11, 11-13, 7-9, and rarely goes above or below.

3. The variations affect all valves in proportion.

4. Upon finding any marked deviation in centimeters in one or two valves from the formula as given one may be justified in concluding either stenosis or insufficiency is present in a given case.

January 27, 1916.

A Leather-bottle Descending Colon, Sigmoid and Rectum.[1]

ROBERT A. KEILTY, M.D.

This case presents a history of incontinence of feces of long duration dependant possibly upon typhoid fever but more probably upon a severe laceration of the perineum at childbirth. Toward the end she has the wasting and cachexia of malignant disease. In the absence of specific data it may be assumed that the condition started in the rectum as an acute traumatic colitis which progressed by extension ulceration until the entire descending colon was involved, leaving a trail of fibrous organization behind. This resulted in denuding the terminal colon of epithelium, and once its protective factors were removed a low grade of chronic inflammation continued. This no doubt allowed absorption of fecal toxins, bacterial or otherwise, with the resultant degenerations and atrophies.

The result of colectomy in this case can only be speculative, but in the early or even moderately advanced stage it would seem that such an operation might be warranted. *January* 27, 1916.

The Numeric Relationship of Infection to the Chemotherapy of Experimental Trypanosomiasis.[2]

JOHN A. KOLMER, M.D., JAY F. SCHAMBERG, M.D., AND GEO. D. RAIZISS, M.D.

(From the Dermatological Research Laboratories of the Philadelphia Polyclinic and College for Graduates in Medicine.)

1. Experiments have shown that in the chemotheraphy of trypanosomiasis there is an important relationship between the number of trypanosomes injected into the test animal and the results of trypanocidal activity on the part of the drug.

[1] Printed in full in the American Journal of Obstetrics and Diseases of Women and Children, 1916, lxxiv, No. 5.

[2] Published in full in the Journal of Infectious Diseases, 1917, xx, 35 to 45.

Digitized by Google

2. This relationship is particularly in evidence in reference to the amount of drug necessary to effect complete sterilization; while rats infected with 500,000 trypanosomes may be sterilized with 0.001 gram arsenobenzol per 100 grams of rat, this is not the case when larger numbers of trypanosomes are injected.

3. The influence of numbers is less marked when the rats are very heavily infected, as with numbers over 2,000,000 trypanosomes. In these instances arsenobenzol retards the appearance of trypanosomes in the peripheral blood but does not sterilize, and the time of appearance of the parasites in the blood is not greatly influenced according to the number used in inoculation.

4. The numerical relationship or infection to the results of chemotherapeutic experiments is therefore a subject of considerable importance and particularly in comparative tests.

Januay 27, 1916.

Various Methods of Illustration as Applied to Medical Works.

ERWIN F. FABER, M.D.

For diagrammatic drawings the pen and ink lends itself particularly well, since its very simplicity and directness gives sharp and clear definition. These drawings reproduce perfectly, and it is well to rely on one-third reduction from the original. Any fault in the cut is more apt to be the fault of the engraver if the lines appear broken. In such cases the cut should be returned, as corrections can readily be made or a new cut demanded. The stipple board (or Ross board) properly belongs in this class, and by its use direct reproduction of the stipple or dots can be obtained without the intervention of a screen.

For photographs and wash drawings, black and white, the screen is used, and when the coarse screen is very objectionable there is a danger in getting it too fine. A screen of 100 to 125 proves very satisfactory. These plates may be retouched by the engraver, and pure whites, as in threads or nerves, etc., will enhance the brilliancy and sharpness. If a half-tone fails, in being too dull, the plate may be etched lighter where desired and the blacks may be burnished darker, according to final criticisms.

The three-color process for illustration again offers possibilities for final criticism, insofar as the predominance of one or the other color may be slightly strengthened by changing the amount of ink used in printing. It is always well to criticise the colored proof submitted by the engraver, as its acceptance makes it the guide that is followed by the publisher, and any error in color cannot be readily remedied when on the press for the edition.

Digitized by Google

By all means the lithograph for color reproduction is best, but unfortunately its cost is almost prohibitive. The great advantage of this method is the many additional colors that are used, and it is not infrequent to use from ten to fifteen color variations, hence the result must be superior to the ordinary three-color method.

In every case in which a drawing has been approved there is no reason why there should be an appreciable loss in the reproduction. Any marked loss should be ascribed to faulty technic, and such a plate should either be altogether refused or criticisms marked on the margin of the proof, indicating lighter etching or where necessary burnishing to darken. To revise a proof carefully means a security for the edition, and authors should insist that the proofs have this O. K. before going to press. *January* 27, 1916.

The Bacteriological Aspect of the Abderhalden Test.

D. RIVAS, M.D., AND A. C. BUCKLEY, M.D.

Following the classical technic of Abderhalden the results were unreliable and uncertain, due usually to bacterial contamination.

The reaction was usually negative when the test was modified by using sterilized placenta tissue and sterile serum, digestion being carried out in test-tubes kept at 37° C. for forty-eight hours, and the dialyzation made in the ice-chest at 5° to 10° C., by which technic bacterial contamination was the exception.

The test was likewise negative when a bacteriological test was applied as follows:

1. A small portion of placental tissue free from amino-acids and suspended in salt solution was tubed and sterilized.

2. 0.5 to 1 c.c. sterile serum of a pregnant woman added and incubated at 37° C. for forty-eight hours. According to Abderhalden the serum of a pregnant woman will digest the placenta during the incubation into amino-acids.

3. Tubes were inoculated with Bacillus coli known to have the property of producing indol from amino-acids and incubated 4 to 5 days at 37° C.

4. Tests for indol in this culture were made in the usual way by using 50 per cent. H_2SO_4 and 0.5 per cent. solution of potassium nitrite. The results obtained are shown in the following table:

Trypsinized bouillon (control)	. . . . .	+	B. coli	=	indol	+
" " "	+ Blood serum (man)	+	"	=	"	+
Salt solution (control) . .	+ " "	+	"	=	"	○
Placenta medium (control) .	. . . . .	+	"	=	"	○
" " (test) . .	+ Blood serum (man)	+	"	=	"	○
" " " . .	+ Virgin " . .	+	"	=	"	○
" " " . .	+ Pregnant serum	+	"	=	"	○

Digitized by Google

It would seem therefore that the ferment claimed by Abderhalden to be present in the serum of a pregnant woman, if present at all, has no appreciable power of digesting placental tissue.

The irregularity and unreliability of the results of the test in the hands of others, in the face of the above results, is probably due to unavoidable technical errors, such as bacterial contamination, etc.

The more exact the technic becomes, that is, when bacterial contamination is avoided, a negative result is the rule, which points, it seems, to the fallacy of the Aberhalden reaction.

January 27, 1916.

Papillary Carcinoma of the Stomach.

JOHN SPEESE, M.D.

Specimen was obtained at autopsy, the history of the case being unknown. The carcinomatous mass extends almost completely around the circumference of the stomach, the papillary mass projecting into the stomach, the lumen being greatly narrowed. The stomach when opened shows that the entire mass measures 11 x 7 x 3 cm. The wall of the stomach at the site from which the papilloma springs is greatly thickened, measuring 1 cm. at its point of greatest diameter.

Microscopic examination shows the usual picture of a papillary type of carcinoma and the wall of the stomach being infiltrated with a typical acini. *January* 27, 1916.

Lymphosarcoma of the Small Intestine.

JOHN SPEESE, M.D.

This and the following cases have been reported in detail in the *Annals of Surgery*, May, 1914.

Specimen was obtained by operation from a man, aged fifty years, who was suffering from symptoms suggestive of chronic intestinal obstruction. The specimen consists of 57 cm. of ileum. The intestine at one area contains a globular mass 8 cm. in diameter, the wall of the intestine is enormously thickened, measuring 3 cm. The section through this thickened portion shows that the intestinal mucosa is greatly ulcerated and that the lumen of the bowel is represented merely by an irregular area of ulceration through the center of the tumor mass. At one point the lumen is almost completely occluded by the tumor tissue. The tumor mass,

Digitized by Google

as represented by the greatly infiltrated wall of the intestine, is composed of firm, whitish tissue which is completely surrounded by the serous coat of the intestine. In the mesentery several enlarged nodes having the same characteristics as the primary tumor are found.

Microscopic examination shows a very cellular formation composed of small, round, deeply staining cells having a fairly uniform appearance. The stroma is composed of thin fibrils which ramify between the tumor cells and extend to the mucosa and infiltrate and destroy the intestinal glands. The structure of the muscular coats of the intestine is completely obliterated by the cellular infiltration. The tumor contains very minute areas of necrosis and is fairly well supplied with new bloodvessels. The lymph nodes removed from the mesentery show a similar involvement.

January 27, 1916.

Myxosarcoma of the Mesentery.

JOHN SPEESE, M.D.

The specimen in this case was obtained from a woman, aged fifty-seven years, operated upon for severe abdominal pain.

The specimen consists of a tumor which is surrounded by a loop of small intestine which measures 80 cm. in length. The tumor, which measures 8 cm. in diameter, is situated near the base of the mesentery and is attached to the intestine for a distance of a few centimeters only. The wall of the intestine appears normal and is not compressed by the tumor mass. On cross-section the tumor is soft in consistency, the cut surface for the most part is white and contains numerous reddish areas and small points of necrosis.

On microscopic examination the growth for the most part is composed of tissue containing large stellate cells. The connective tissue in these areas is of very loose texture and contains within its meshes a homogeneous substance taking a faint blue stain. Large numbers of bloodvessels with thin walls are present. A considerable amount of free blood is found in the fibrous tissue. In addition to the stellate cells mentioned there are many areas in which large numbers of cells are closely packed together, the cells being spindle in type, some are large, some small, and many being arranged around the bloodvessels. Minute areas of necrosis are encountered, and in these situations leukocytes are found between the tumor cells. Many non-striated muscle fibers are seen in the more superficial portions of the tumor. *January* 27, 1916.

Digitized by Google

Carcinomatous Degeneration of Papilloma of the Cecum.

JOHN SPEESE, M.D.

A woman, aged thirty years, was admitted to the hospital with symptoms of acute intestinal obstruction. Operation revealed an obstruction due to intussusception of the ileum into the cecum. The ileum and cecum were excised and examination of the specimen showed the following:

At the ileocecal junction, beginning at the base of but not involving the lumen of the appendix, is a round tumor measuring at its base 4 cm. and projecting into the lumen of the cecum for a distance of 3 cm., the surface is covered with mucosa which presents small areas of ulceration. The mass partially obstructs the entrance of the ileum into the cecum, although the true obstruction was due to the intussusception predisposed to by the presence of the papilloma. Cross-section showed that the tumor was composed of firm whitish tissue which seemed to extend into the wall of the cecum.

Microscopic examination of sections taken in this region (wall of the cecum) showed that an early form of carcinomatous degeneration had arisen. In this situation atypical and greatly enlarged glands were found. *January* 27, 1916.

Sarcoma of the Rectum.

JOHN SPEESE, M.D.

Specimen was obtained from a middle-aged woman whose symptoms suggested carcinoma of the rectum, as she was suffering from a lesion of the lower bowel which produced the usual symptoms of obstruction in this situation.

Specimen removed by operation consisted of an irregularly rounded, reddish, fleshy tumor attached to the posterior portion of the rectum, the mass filling the lumen of the bowel, causing almost complete obstruction. In the opened specimen the tumor measures 10 x 7 x 5 cm., is firm and fleshy in consistency, deep red in color, and contains superficial points of ulceration. The growth is distinctly pedunculated. The pedicle is broad and extends across the entire posterior surface of the rectum. The tumor is situated in the upper portion of the rectum about 12 cms. from the anal border.

Microscopic examination shows a very cellular formation consisting of small spindle cells closely packed together, the tissue being very vascular and containing small amounts of necrosis.

Diagnosis: Spindle-cell sarcoma. *January* 27, 1916.

Digitized by Google

Gliomatous Tumor of the Brain.

ALFRED GORDON, M.D.

At autopsy a large soft vascular tumor was seen involving the supramarginal gyrus, angular gyrus and the posterior thirds of the first and second temporal lobes and a very small portion of the occipital lobe. A section shows that the very posterior portion of the internal capsule and the corona radiata are involved by the tumor. The lenticular zone of Marie appears intact. The tumor itself is gliomatous in character. It is circumscribed, contrasting strikingly through its consistence and color with the normal tissue. Histologically a large number and densely arranged glia cells are seen here and there. Necrotic areas are seen especially at the periphery. Cyst formations are multiple and in their immediate vicinity there is rarefaction of the glia stroma. The case is unusually instructive from the stand-point of the problems of transcortical aphasia and of Marie's newer conception of aphasia.

February 10, 1916.

Skin Cancer in a Gas-trap Cleaner.

D. L. FARLEY, M.D., AND J. HAROLD AUSTIN, M.D.

The case presented in this communication was that of a worker in a gas works whose job was that of cleaning out the tar traps. He exhibited over the forearms and chest the typical papular, warty lesions characteristic of workers in certain types of tar. Contrary to the rule, the scrotum in this individual was not involved. The patient had experienced at the onset of the condition, the characteristic burning and smarting upon leaving his work and passing through the sunlight and air to his home.

February 10, 1916.

Hydrops Tubæ Profluens.

F. B. BLOCK, M.D., AND THOMAS H. LLEWELLYN, M.D.

At operation there was found a right tube which was dilated and contained fluids, and an ovarian cyst on the left side. A supravaginal hysterectomy, right salpingostomy and left oöphorectomy was done. After the operation the uterus was opened, gentle pressure made on the dilated right tube, and watery fluid was seen to jet from the right uterine ostium, thus proving to us the diagnosis was correct. The object of presenting this case was because it is a rarity, and the fact that the diagnosis was made before operation.

February 10, 1916.

Digitized by Google

Fatty Tumor of Mesentery Causing Intestinal Obstruction.

GEORGE M. DORRANCE, M.D.

This tumor, the size of a grapefruit, was removed from the mesentery approximately one foot above the ileum. It was attached for three inches to the intestinal edge of the mesentery. Pathological diagnosis: Pure lipoma. *February* 10, 1916.

Studies in Bence-Jones Proteinuria.[1]

A. E. TAYLOR, M.D., AND C. W. MILLER, M.D.

(From the Department of Physiological Chemistry, University of Pennsylvania, Philadelphia.)

Under the conditions of the above experiment there is a continued precipitation from the temperature at which the Bence-Jones protein commences to come out up to the coagulation point of serum protein. This may be explained either by assuming that the Bence-Jones protein is composed of various fractions with different coagulation points, at least with different rapidity of precipitation; or, on the other hand, that the continued action of the acid had resulted in gradual change of the order of acid-albumin formation.

It seems evident, therefore, that heating the Bence-Jones protein with even very moderate quantities of acetic acid is capable of effecting a change in the nature of the protein such that the temperature at which it coagulates is raised; but this in no way interferes with its characteristic behavior in regard to going into solution by boiling and reprecipitating on cooling.

Spiegler's solution, Roberts' reagent, and acetic acid and ferrocyanide all cause immediate heavy precipitation when used with the native urine; and all are capable of indicating minute traces of this protein. This is of course what would be expected, and is mentioned only because of the fact found by Folin and Denis that the Bence-Jones protein gave no precipitate with acetic acid and ferrocyanide except after long standing.

The marked anaphylactic activity of this protein confirms the belief that we are dealing with a higher protein of individual biological stamp and not with a degradation stage in the hydrolysis of any body protein.

If the Bence-Jones protein is to be regarded as foreign to the tissues of the subject, we should by the Abderhalden hypothesis expect that a special ferment would soon be aroused to destroy it

[1] Printed in full in the Journal of Biological Chemistry, 1916, vol. xxv, No. 2.

Digitized by Google

in the body; and certainly there would seem to be nothing in the nature of the substance itself to resist such a fate. Yet instead of being digested, large quantities of it are excreted in its native condition, apparently free from any hydrolysis; and this can continue indefinitely. Under such circumstances we must dismiss the idea of a protective ferment.

From every point of view it is clear that this substance in our case as in others is a higher protein, a human product closely related to the normal blood proteins. *February* 10, 1916.

The Clinical Significance of Bence-Jones Protein.

T. G. SCHNABEL, M.D.

Seventy-one cases have appeared in the literature since Bence-Jones reported the first case before the Royal Society of London in 1847. This substance has the properties of a globulin and appears in the urine of patients suffering with multiple myeloma. Kahler's disease and myelopathic albumosuria are two other synonyms applied to this condition.

The great similarity in all of the reported cases permits the construction of a simple picture as applying to the symptomatology of the disease. It is principally to be differentiated from osteomalacia and the prognosis is utterly bad. Only one of the cases in the literature has lived much over two years.

The Bence-Jones protein is apparently a metabolic product of the tumor cells, and as such appears in the urine in percentages ranging from 0.25 per cent. to 6.5 per cent. The amounts found remain independent of food intake.

The appearance of the Bence-Jones protein in the urine is almost pathognomonic of multiple myeloma. A few cases of leukemia, sarcomatosis, and carcinomatosis have been reported as yielding this substance. *February* 10, 1916.

Chloride Retention without Edema; Report of a Probable Case.

O. H. P. PEPPER, M.D.

The case reported falls in an ill-defined group with variable symptoms in whom some relief is obtained by lowering the daily intake of sodium chloride. Quantitative studies of this patient's chloride output and chloride in the blood showed some retention in the blood and a very large output. Some improvement in the patient's condition followed reduced salt intake. There was never any true edema, but occasionally a patch of local brawniness which had been considered in the nature of angioneurotic edema. *February* 10, 1916.

Digitized by Google

The Clinical Importance of Chloride Retention.

C. C. WOLFERTH, M.D.

February 10, 1916.

A Clinical Hemoglobinometer.

HERBERT HAESSLER, M.D., AND HARRY S. NEWCOMER, M.D.

(From the Ayer Clinical Laboratory of the Pennsylvania Hospital.)

We have adopted the principle of the Sahli hemoglobinometer, modifying it to satisfy the usual concepts. The Sahli instrument has the advantage that it offers a comparison color of the same material as the sample, and a color to whose shade variations the eye is particularly sensitive. It has the disadvantage of uncertainty of comparison, due to the fact that one cannot reconsider a discarded choice. Therefore, instead of the single standard tube, we use eleven comparison tubes, whose densities correspond to readings varying by 10 from 10 per cent. to 110 per cent. hemoglobin. The standard fluids are made up according to Sahli's specifications. The tube marked 100 per cent. contains in 100 c.c. the equivalent in hematin hydrochloride of 17.2 grams of hemoglobin. Sahli bases his percentage readings on blood containing 17.2 grams hemoglobin per 100 c.c. Such a blood diluted 1 to 100 would then correspond exactly with the mixture in our 100 per cent. tube.

Our procedure for the preparation of the standards is as follows: 10 c.c. of human blood are drawn from a vein into a certified pipette and immediately emptied into and rinsed in 100 c.c. of tenth-normal hydrochloric acid. At the same time, from the same vein, 2 c.c. of blood are drawn into a 2 c.c. pipette and emptied and rinsed in 400 c.c. of 1 per cent. sodium carbonate solution. This latter solution is then calibrated on a Fleischl-Miescher hemoglobinometer and the hemoglobin of the blood determined in grams per 100 c.c. The hydrochloric acid mixture is then made up with tenth-normal hydrochloric acid in dilutions corresponding to 17.2 grams hemoglobin per 100 c.c. of fluid for the 100 per cent. tube and fractions of that for the other tubes.

The hematin hydrochloric is insoluble and forms a fine suspension. This settles easily. For that reason beads are enclosed in the tubes so that the fluid can easily be made homogeneous by a little shaking. It is impossible to seal the tubes off short above the fluid. A very satisfactory and simple method is to partially close them and then seal with a plug of paraffin dropped in from a

Digitized by Google

pipette. Experiment showed that the eye can most readily compare colors in the form of vertical rectangles, and the size and shape eventually used seems to be the most fortunate one. The tubes are made from glass tubing which to the eye has a uniform thickness and whose outside diameter (about 7 mm.) does not vary by more than 0.1 mm. Such tubing is easy to pick out of ordinary stock.

The tubes are conveniently arranged in a rack, so that the comparison tube can be slipped in between any two of them. The frame is of red vulcanized fiber, which is cheaper and more durable than gutta-percha, and whose color does not seem to be objectionable. Septa between the tubes and opal glass behind them are omitted. The omission makes the construction simple and at the same time facilitates the reading. Light transmitted through a screen is not as good as reflected light obtained by placing the instrument on a sheet of paper, as is done in ordinary titration.

The dilution of the patient's blood can be done with an ordinary red blood pipette, using tenth-normal hydrochloric acid as a diluting fluid. A dilution of 1 to 100 is made. The red blood pipette will deliver enough fluid to fill the comparison chamber, and it offers a convenient and accurate instrument for the purpose, with the additional advantage that it is readily obtainable and usually already in the possession of the individual.

The readings can be made in any light readily and with certainty to a multiplle of 5, or, in other words, to within 2.5 of the correct percentage. *February* 24, 1916.

Differential Blood Picture in Parasitic Skin Diseases and Their Possible Significance.

ALBERT STRICKLER, M.D.

This study was undertaken with the hope of throwing some light on the blood picture of ringworm of the scalp, also favus as well as the animal parasitic diseases of the body.

The blood picture of scabies had already been studied by Dr. Jay F. Schamberg and the author. In their communication, reporting some 47 cases, 80 per cent. showed an eosinophilia of 5 per cent. or over.

In the study of the blood picture of ringworm of the scalp, the predominating picture was the large increase in the number of small lymphocytes. In this communication the ringworm patients were divided into two divisions: (1) those who were treated with vaccine only and (2) those who received local treatment alone.

Twenty-seven patients were treated with vaccines. The average percentage of small lymphocytes was 38.8 per cent. and the high-

Digitized by Google

est individual count was 56 per cent. In this series only 4 did not show an increase of small lymphocytes.

There were 23 patients suffering with ringworm of the scalp who received local treatment only. The average increase of small lymphocytes in this series was 37.2 per cent.; the highest individual count was 52 per cent. In this group 6 patients did not show an increase in the small lymphocytes.

In grouping the entire series of 60 patients the average count of the small lymphocytes was 37.4 per cent.

Fourteen patients suffering with pediculosis corpus were studied and nothing significant was noted in the blood picture.

Four patients with favus of the scalp were studied, and while 3 showed an increase of small lymphocytes, the cases were too few to permit of any conclusions.

All the slides were stained by eosin, hemotoxylin method. Two hundred cases were counted, and Cabot's standard of the normal blood picture was followed.

The almost uniform increase of small lymphocytes in ringworm of the scalp may be used as an aid in the diagnosis of this affection.

February 24, 1916.

The Fate of Large Quantities of Blood Introduced Into the Peritoneal Cavity.

J. E. SWEET, M.D., AND M. M. PEET, M.D.

The experiments were undertaken to discover by what route the red blood cells so often left after abdominal operations are removed from the peritoneal cavity. The older pathologists taught that red cells were taken from the peritoneal cavity and returned to the blood stream, although the exact route followed was not clearly stated; the younger pathologists, influenced no doubt by the studies on hemolysis, have assumed that the blood cells would be taken up by hemolysis and removal of the detritus by wandering cells.

We placed a cannula in the thoracic duct, close to the point at which the duct empties into the venous system; after assuring ourselves of a flow of perfectly clear lymph, 50 to 100 c.c. of the animal's own blood, defibrinated, was injected into the peritoneal cavity. In from twelve to thirty minutes blood is macroscopically evident in the thoracic duct lymph and rapidly increases in quantity until the lymph assumes the appearance of blood itself.

One hundred cubic centimeters of defibriated blood will have almost completely disappeared from the peritoneal cavity in twenty-four hours.

The blood cells are taken into the lymph apparatus of the diaphragm, to the extent that the subpleural surface of the diaphragm

Digitized by Google

assumes the appearance of extensive hemorrhage beneath the pleura; the lymph vessels of the pleural covering of the diaphragm are seen filled with blood. The movements of respiration are essential to this withdrawal of blood from the belly cavity, since after death a clear lymph will flow from the cannula.

February 24, 1916.

Changes in the Thyroid Gland following Intoxication by Toxic Protein Derivatives.

A. L. TATUM, M.D., AND J. E. SWEET, M.D.

In animals killed by obstruction of the duodenum, and in animals killed by the intravenous injections of the material found in the loops, the thyroid glands undergo marked changes in morphology and staining chacteristics. The essential features of the altered thyroid glands are as follows: (1) rupture of alveolar walls with extravasation of colloid material into the extra-acinar tissues; (2) desquamation of the epithelium, frequently with great enlargement of certain of the cells; (3) hyperemia in certain instances; (4) parathyroid and thymus glands, serving as a control against a generalized reaction, appear normal, aside from a variable account of hyperemia.

A few instances of ligation of the pancreatic ducts, acute pancreatitis, excision of the stomach associated with excision of the pancreas, and acute generalized peritonitis, resulted in thyroid changes similar to that described above.

The poisonous material from the duodenum is manifestly a product of protein cleavage, but whether it is a normal product of protein digestion, an abnormal product due to the conditions of obstruction, or a bacterial product, is not yet certain.

February 24, 1916.

Skin Cancer in Chimney-sweeps, Paraffin Workers and Allied Trades, etc.

ALFRED STENGEL, M.D., AND J. HAROLD AUSTIN, M.D.

The case which we present tonight is an instance of an industrial disease which affects workers in crude coal tar, pitch, and paraffin oil, and which is supposed to be closely related to the condition known as chimney-sweep's cancer. It has been observed among those engaged in the distillation of paraffin and tar, in the manufacture of patent tar briquettes for fuel purposes, in the dis-

Digitized by Google

tillation or handling of crude lubricating oils, in gas works from the handling of the gas works tar and pitch and the gas oil, in the manufacture of tar paper and in certain textile mills where the fabrics are soaked in crude paraffin oil.

The disease exhibits three stages. Many of the workers in the above-named industries notice almost immediately upon entering the industry that the face, hands, and arms upon exposure to the sun and wind burn intensely, so that to walk into the open on a clear day after such work is extremely painful. This stage is uncomfortable but not dangerous, and is said to be almost universal among such workers. In the second stage the skin of the hands, arms, face, breast, and also of the scrotum exhibits an eczema becoming dry, harsh, and dusky gray. The ducts of the sebaceous glands become plugged with black masses which clog the widened orifices. The skin becomes scaly, resembling psoriasis or there may be an acne-like eruption. Here and there about the plugged sebaceous glands there develop epithelial proliferations, giving rise to hard, pointed warts, tender on pressure and about the size of a grain of barley or to larger flat warts that have been compared to drops of wax. If these warts be removed, as is often done by the patient, the base is somewhat ulcerated, and there is left a scar more or less pigmented. After some months of the work, the burning sensations of the first stage disappear, but the warts continue to develop. Finally, usually after several years of the work, one or more of these warts may undergo epitheliomatous degeneration. This is especially prone to occur on the scrotum, but has also been described on the arm, as in the case we report, on the lips and elsewhere. Like the chimney-sweep's cancer, these epitheliomata are slow growing, relatively benign tumors, exhibiting a tendency to ulceration and giving at least for a long time no metastasis even to the regional lymph nodes. The latter show sometimes, however, an inflammatory hyperplasia.

February 24, 1916.

The Formation of Specific Proteoclastic Ferments in the Blood in Response to the Parenteral Introduction of Foreign Proteins.

ALONZO E. TAYLOR, M.D., AND FLORENCE HULTON.

The Abderhalden reaction in its original form, *i. e.*, testing a dialysate with ninhydrin, is open to criticism on the fact that ninhydrin may react with substances other than the products of a proteolytic digestion; saliva will give the reaction. To avoid this reagent the following technic was evolved: The experimental ani-

Digitized by Google

mals were given three injections, a week apart, varying from 200 to 800 mgs. of a pure protein, either in solution or suspension in Ringer's solution. All precautions were taken to insure aseptic conditions. The animals were bled to death from the carotid on the day following the last injection, as were the control animals.

The blood was centrifuged and a portion of the serum was incubated with 1 gm. of the particular protein. The non-protein nitrogen was determined in a portion of the blood before incubation and in a portion after incubation for forty-eight hours. An increase of non-protein nitrogen in the serum of the experimental animal would indicate a rise in nitrogen due to a digestion of the protein by the serum.

The results obtained by us indicated clearly that whatever reaction might be induced in the blood in response to the injection of the protein that this reaction was not one of digestion in the case of protamine, phaseolin, soy bean globulin, gliadin, casein, edestin, milk albumin, and Bence-Jones protein. This would seem to show that the statement that in pregnancy and after the injection of a foreign protein protective ferments of a proteoclastic nature arise in the blood is not borne out by the experimental facts.

February 24, 1916.

Observations on the Influence of Angle of Section on Measurements of Cortex Depth and on the Cyto-architectonic Picture.

SAMUEL T. ORTON, M.D.

The study of the cortex in the defective and demented cases has been attempted by various methods. Architectonic approach the most promising. Hammarberg's method and results. His method of enumeration in a given cubic volume failed to control variations in the intercellular elements. These elements are of two types, the essential nervous and the nutritive and supportive. Embryological and pathological considerations suggest that the proportions of these two types may be modified. Possibility of the application of a threefold correlation between cell numbers, cell size, and cortex depth. Some observations to determine influence of obliquity on cortex depth give an average error of 6 per cent. of which about 3 per cent. is due to difficulty in demarcating cortex from medulla. Cyto-architectonic picture very little modified. Truncated cells in large proportion give an index of obliquity which will probably control errors of considerable size, but not the smaller ones.

February 24, 1916.

Digitized by Google

Giant-cell Glioma of Brain.

A. G. ELLIS, M.D.

The brain is from a man, aged twenty-six years, brought to hospital unconscious and operated upon to relieve intracranial pressure. No tumor was found and death occurred in five days. Examination of brain revealed a tumor 6 cm. in diameter, in the left parietal lobe and encroaching on lateral ventricle and optic thalamus.

Microscopically the tumor is chiefly of large cells from 40 to 160μ in diameter. They possess one to several nuclei and often many irregular fragments of chromatin. The nuclei are excentrically placed. Cell inclusions, ranging from leukocytes to smaller tumor cells, are also numerous. Many of these large cells have cytoplasmic processes, chiefly small but in one instance being 175μ long and 7μ wide. *March* 9, 1916.

Carcinoma of Lung Simulating Chorio-epithelioma.

A. G. ELLIS, M.D.

The specimen is from a man, aged twenty-six years, in whom the clinical diagnosis was pulmonary tuberculosis. The anatomical diagnosis was primary carcinoma of right lung with metastases to left lung, liver, mediastinal and retroperitoneal lymph nodes.

The upper three-quarters of the lung is occupied by a new growth of soft gray tissue with reddish areas, the lower fourth containing a few isolated nodules. Microscopically the growth is of epithelial cells arranged in masses or surrounding palely stained connective tissue stalks in a way that is very suggestive of placental villi. These areas are rich in extensive lakes of blood.

March 9, 1916.

Amebic Dysentery.

THOMAS MCCRAE, M.D., AND D. M. DRY, M.D.

The dysentery in this case had existed for twelve years. During this time the symptoms had varied in occurrence, there being periods when the patient was apparently well, at other times there had been very acute exacerbations. The final attack persisted for about four months. When the patient came under observation he was very seriously ill and had frequent stools, the majority of which only consisted of mucus and blood. There was a great deal of vomiting and hiccough with severe abdominal pain. We were not

Digitized by Google

able to find amebæ in the stools. The perforation of the colon occurred when the patient was moribund and there was no question of any possibility of operation being done. Emetine treatment had been very thoroughly employed at different times, apparently without any benefit. *March* 9, 1916.

Hypernephroma of the Lung Secondary to Hypernephroma of the Adrenals.

A. C. MORGAN, M.D., AND D. M. DRY, M.D.

A. W., colored, aged thirty-seven years, admitted to the tuberculosis wards of the Philadelphia General Hospital August 13, 1915. Family history negative. Occupation, hod-carrier, with pressure on shoulder while carrying the hod.

History of injury two years prior in having a horse fall on him, disabling him for two weeks.

Entire right side of the body was much larger than the left, with clubbing of fingers and toes. Pain in shoulders, elbows, and wrists. Mentality clear, though cerebration was slow. Late in disease incontinence of feces and retention of urine, with a large atrophic decubitus, which spread rapidly and involved the scrotum and penis.

Sputum was repeatedly negative for the tubercle bacillus, only one specimen showing a positive report and this may have been an accidental contamination in the ward. Physical signs were those of consolidations and adhesions of right upper lobe. *X*-ray report showed periostitis of bones of hands, with complete consolidation of upper and middle lobes of right lung and infiltration of left apex. Terminal symptoms were those of the typhoid status.

March 9, 1916.

Foreign Body (Roofing Nail) in Right Bronchus for Two and a Half Years.

E. D. FUNK, M.D.

In September, 1912, the patient, a carpenter, while doing some overhead work with two nails in his mouth, felt his support giving way and in his effort to save himself, swallowed the nails. This brought on a fit of coughing lasting about three minutes, in which time he had some difficulty in getting his breath, but succeeded in coughing up one of the nails. He returned to his work. The nails were approximtely $1\frac{1}{4}$ inches in length, with a head about the size of a Canadian 5-cent piece. The presence of the nail in the bronchus

Digitized by Google

gave rise practically to no disturbance except that the patient states the wheezing quality of his breathing, shortness of breath, and cough from which he had suffered beforehand, were now somewhat exaggerated. He came to the hospital in September, 1914, complaining of these symptoms, with the addition of expectorating a considerable amount of badly smelling sputum. He never spit or vomited blood.

Six months later the patient died, and at autopsy the nail was found in the anterior branch of the right bronchus, the head being well embedded in the swollen mucous membrane. Other findings were a septic bronchitis; septic pneumonia; interlobar empyema and chronic adhesive pleuritis. *March* 9, 1916.

Diverticulum of Esophagus.

E. D. Funk, M.D.

Before the accident the patient states that he had at times difficulty in swallowing solid food, and also that when he would drink water he could feel it stop in the chest and then in a few minutes pass on to his stomach. How much this had to do with the diverticulum is questionable. *X*-rays show the diverticulum in close relationship to the nail.

The outpouching of the esophagus was evidently caused by traction from a large fibrocaseous lymph gland situated just beneath the bifurcation of the trachea. *March* 9, 1916.

Odontomas.

Charles N. Bonney, M.D., and A. G. Ellis, M.D.

These growths are clinically benign, although pathologically sometimes suspicious of malignancy. They can be successfully operated by incisions through the mouth, thereby avoiding external disfigurement. In one of the two cases reported the lower lip and tissues attached to the chin were turned down like a curtain over the margin of the mandible, thus giving an ample field of exposure.

The classification is in a very confusing condition. The most comprehensive is that of the Committee of the British Dental Association in 1914. They do not use the term adamantinoma, classifying all the epithelial odontomas as cysts.

March 9, 1916.

Digitized by Google

A Study of the Cholesterol Content of the Serum in Gall-bladder Disease.

MARTIN E. REHFUSS, M.D., AND P. B. HAWK, PH.D.

Owing to the interest attached to the studies of Chauffard, which seemed to indicate that there was present in cholelithiasis a hypercholesterolemia, we made a study of the blood serum of a number of cases, using both subjects with and without demonstrable cholelithiasis. Chauffard in an exhaustive study came to the conclusion that the excess of cholesterol was one of the most important etiological factors in the production of stone, and explains it on the basis of (1) of a disturbance in the liver cell itself producing an insufficiency of bile salts, or, as he terms it, "cholic acid forming insufficiency;" (2) the insufficiency of bile salts which are the principal agents concerned in keeping the cholesterol soluble in the serum results in cholesterol retention in the serum; (3) owing to hypercholesterolemia an excess of cholesterol appears in the bile, with a tendency toward the precipitation of cholesterol insufficiently maintained in solution in the gall-bladder. Stasis and infection can then act with the above factors.

Our studies in 16 cases of cholelithiasis showed in every instance a hypercholesterolemia varying from slightly above the normal 160 to 180 mgm. per 100 c.c. of serum to as high as 800 mgm. In 8 of these cases submitted to operation stone or definite concrements were found varying from a mass of fine sandy cholelithiasis material in one case, one large stone in another case, to a very severe case with over 700 stones. In the other 8 cases the diagnosis seemed justifiable by the nature of the attacks, biliary colic, jaundice, bile in urine, clay-colored stools and steatorrhea. Two of these passed calculi. In 28 cases with conditions other than stone, serum studies, showed low cholesterol findings in every case, with the exception of a case of atrophic cirrhosis with ascites in which there was 200 mgm. and in a very difficult case of duodenal ulcer, in which the ulcer was demonstrable, and in which there was present pronounced adhesions to the gall-bladder. No stone was found, however. It is interesting to note that in four of these cases, with almost typical history of cholelithiasis, and in which the surgeon made that diagnosis, serum examination disclosed low cholesterol and operation showed no stone. These findings agree closely with those of Chauffard and seem to indicate that the study of the serum is of positive diagnostic value in cholelithiasis.

It is believed the cholesterol is both endogenous, due to suprarenal, and in women corpora luteal activity, and exogenous, due to the ingestion of a cholesterol-rich diet. *March* 9, 1916.

Digitized by Google

Further Report upon Calcium and Parathyroid Medication in Tuberculous Guinea-pigs.

R. C. ROSENBERGER, M.D., AND P. S. PELOUZE, M.D.

The series of experiments reported before this Society March 25 were repeated exactly as before and the results were essentially the same, the gain in weight of the treated animals being far in excess of that of the tuberculous control.

One tuberculous control and one parathyroid and calcium pig were exhibited and their respective gains since the beginning of the experiments were 97 gm. and 482 gm. *March* 9, 1916.

Pyorrhea Alveolaris.

JOHN A. RODDY, M.D., ELMER H. FUNK, M.D., AND DAVID W. KRAMER, M.D.

Pyorrhea alveolaris is not a specific disease; its chief etiological factors being (1) an excessive bacterial flora of the mouth, (2) deviations from normal of the affected tissues brought about by certain diseases, particularly tuberculosis, which disease shows a coexisting pyorrhea in 80 per cent. of cases; also diabetes having 77 per cent. Syphilis from our experience is not included in this group of diseases.

We agree with the recent writers that ameba, although it is found in many cases, is not the etiological factor as the cause of pyorrhea. Its disappearance after emetine treatment does not cure the condition.

There is always an excessive bacterial flora in the mouth in pyorrhea; spirilla and staphylococci are more frequently found and form a larger proportion of the whole baeterial flora in pyorrhea and oral sepsis than in normal mouths.

As to clinical aspects of pyorrhea, various conditions mentioned by previous writers have been confirmed, *e. g.*, arthritis, gastric disturbances, anemia, tonsillar infections, neuritis, albuminuria, and furunculosis have been found in patients having this condition.

To treat successfully we must resort to oral hygiene, the institution of dental treatment, which may be necessary, and medical treatment of the coexisting systemic disease. A combination of these measures is essential. Autogenous vaccines with the above was beneficial in 20 per cent. of cases; when used alone it had no especially beneficial effect upon the condition. *March* 9, 1916.

Digitized by Google

Massive Pleural Effusion.

J. PARSONS SCHAEFFER, M.D., AND E. H. FUNK, M.D.

March 9, 1916.

Hemothorax Due to Ruptured Aortic Aneurysm.

J. PARSONS SCHAEFFER, M.D., AND E. H. FUNK, M.D.

March 9, 1916.

Single Kidney.

J. PARSONS SCHAEFFER, M.D., AND E. H. FUNK, M.D.

March 9, 1916.

Adrenals Showing Lesions Found in Pellagra.

W. M. L. COPLIN, M.D.

March 9, 1916.

Urinary Calculi with Foreign Body Nuclei.

W. M. L. COPLIN, M.D.

March 9, 1916.

Specimens of Tubal Pregnancy.

GEO. W. OUTERBRIDGE, M.D.

1. Unruptured ampullar pregnancy containing an embryo 9 mm. in length.

2. Unruptured ampullar pregnancy containing an embryo 35 mm. in length. This specimen shows an unusually well-developed tubal placenta, with very little blood clot.

3. Ampullar pregnancy, containing an embryo 18 mm. in length, in the act of "tubal abortion." The embryo is contained in an amniotic sac about 4 cm. in length, this in turn lying in a mass of blood clot and placental tissue measuring 7 x 3.5 cm. This mole is being extruded from the greatly dilated fimbriated extremity of the tube, lying just about half within the tube lumen, and half projecting beyond the fimbria.

4. Very early pregnancy, ruptured, occurring near the uterine end of a very slightly enlarged tube. The abdominal extremity of

Digitized by Google

the tube is closed, and the corpus luteum is in the ovary of the opposite side, suggesting the possibility of the pregnancy having arisen as a result of so-called "internal migration" of the ovum.

5. A case of pregnancy which has occurred in the portion of the tube which passes through the uterine wall—so-called "interstitial" or "isthmic pregnancy." Rupture has taken place upward, the opening being on the fundus of the uterus just at the tubo-uterine junction. *March* 23, 1916.

Carcinosarcoma Uteri.

GEO. W. OUTERBRIDGE, M.D.

Specimen of a somewhat enlarged uterus removed from a woman, aged seventy-three years. The uterine cavity is distended by a soft, friable, partly necrotic submucous tumor about 7 cm. in diameter, which has at one point completely penetrated the uterine wall, appearing on the external surface as a small, mushroom-like projection in the region of the fundus. Sections through the major portion of the tumor show it to be composed of loose, very cellular tissue, the cells presenting considerable degrees of polymorphism. Throughout this tissue are numerous greatly engorged bloodvessels, and some whose lining endothelium shows considerable swelling. The appearance of this tissue is that of a mixed-cell sarcoma. Sections from the peripheral portions of the tumor show, on the other hand, a broad zone of typical adenocarcinoma, such as usually arises from the endometrium. For the most part the stroma in the carcinomatous areas is fibrous, and not sarcomatous, but here and there distinct masses of adenocarcinoma can be seen invading the sarcomatous tissue. It is probable that the sarcoma has arisen on the basis of a submucous myoma, the endometrium covering which has become carcinomatous, the two tumors thus arising independently, and happening at a few points to come into immediate contact. *March* 23, 1916.

Congenital Vaginal Cysts.

F. E. KEENE, M.D.

The cysts in this case were bilateral, extended from each vaginal fornix downward along the anterolateral vaginal walls to within three centimeters of the vulvar orifice. They were definitely encapsulated and contained clear fluid. Microscopically, the lining membrane consists of flattened-out cells or is entirely lacking, due obviously to pressure. The position and shape of these cysts warrant the conclusion that they arose from Gärtner's ducts.

Digitized by Google

Cysts of the vagina are, as a rule, of pathological rather than clinical interest since they rarely develop to large size. When symptoms are present, they are usually due to infection and abscess formation.

Small cysts with turbid contents are commonly found in the posterior vaginal wall and arise from inclusions of epithelium in scar tissue following laceration of childbirth or operation. True glands are occasionally present in the vagina and give rise to small cysts with clear or turbid contents of varied distribution in the vaginal wall. In addition to the type arising from Gärtner's duct, other embryological structures may lead to cyst formation.

Very rarely a rudimentary Müllerian duct persists in the wall of a fully developed duct, and dilatation of the former leads to the formation of a cyst. Lastly, the blind end of a misplaced ureter can dilate sufficiently to produce a small cyst in the anterolateral vaginal wall. *March* 23, 1916.

Multiple Large Aneurysms.

BALDWIN LUCKE, M.D., AND W. L. FRANCIS, M.D.

Postmortem Examination. The following conditions were noted at autopsy: Just above the origin of the innominate artery an aneurysm, the size of a lemon, which adhered to the sternum and vena cava and perforated into the vena cava. An aneurysm on the left subclavian artery and somewhat less in size, which by gradual and constant pressure against the first rib, caused obliteration of this artery; an aneurysm of the thoracic artery, partially eroding fifth to seventh thoracic vertebræ, and being tightly adherent to the eroded vertebræ. Aorta throughout its course shows innumerable roundish, yellowish-white elevations, and when held against the light, distinct thinning in and between the tubular swellings are seen. Heart and other organs showed nothing of interest.

March 23, 1916.

Squamous-cell Carcinoma, Derived from the Epithelial Lining of a Dermoid Cyst of the Ovary.

DAMON B. PFEIFFER, M.D.

The specimen consists of the left Fallopian tube, with a cyst ovoid in shape, measuring 12 x 12 cm., also a section of the sigmoid 3 cm. long and from 7 to 9 cm. in diameter. The sigmoid at one portion is thickened and the wall is continuous, with a somewhat friable, formless mass of grayish tissue. The cyst in part

Digitized by Google

possessed a smooth, serous coat, but at another area, about 4 cm. in diameter, was nodular and showed a broken area of the same variety of tissue, as was noted on the sigmoid, with which it had been continuous prior to the operation.

The sigmoid showed no internal ulceration. The contents of the cyst was hair and the grumous material characteristic of a dermoid. The cyst wall was thin, except at the nodular area, which varied up to 4 cm. in thickness.

Microscopically. Sections through the thickened area of the cyst show an infiltrating typical squamous-cell carcinoma. The same growth also infiltrated the sigmoid at the point of adherence.

The gross appearance, the microscopic character and the absence of squamous epithelium in this location, except in the lining of the dermoid cyst are conclusive as to the origin of the tumor in its epithelial lining. *March* 23, 1916.

Experimental Studies in Tissue Ferments.

E. Asnis, M.D., Anna Freese, M.D., and John A. Kolmer, M.D.

March 23, 1916.

A Preliminary Report upon the Toxicity of the Contents of Ovarian Cysts.

J. T. Leary, M.D., H. J. Hartz, M.D., and P. B. Hawk, Ph.D.

The object of this work was to ascertain whether any of the several varieties of ovarian cysts contained toxic substances, and if so, the isolation and identification of these substances. Accompanying this study, an analysis of the chemical constituents of the cysts was also made whenever the contained fluid seemed of sufficient interest. Bacteriological studies were made upon the contents of each cyst. Several varieties of cysts were studied, namely, three multiple proliferating cyst adenomata, one papillary proliferating cyst, one multiple follicular cyst, one simple cyst of ovary. The study of the toxicity of the cyst contents was made by the intraperitoneal injection of 10 c.c. of the contents into guinea-pigs, the effect upon the experimental animals being judged by the subsequent weight and temperature. Glycerol bouillon, gelatin and glucose, glycerol agar, were used in the bacteriological studies. The chemical examination consisted, as a rule, in the identification of the protein contents of the cystic fluid. The results obtained were that the contents of the different cysts were sterile in each case.

Digitized by Google

The cysts examined showed no toxicity, regardless of the nature of their contents. No rise of temperature nor loss in weight was noted in any guinea-pig after the injection. The animals were killed about twelve weeks after injection and no lesions could be determined microscopically.

In two cases the physical nature of the contents was mucilaginous in the extreme, having the physical appearance of a mucin substance. That this property was due to the globulin content and not to a mucin substance was shown by the precipitating properties and coagulability of the substance in question, accompanied by the lack of viscosity in the resulting filtrates. A slight amount of pseudomucin was obtained in each case, but the trace present could in no way account for the physical characteristics of the contents. *March* 23, 1916.

The Value of Metabolic Studies for the Prognosis of Splenectomy in Pernicious Anemia.

O. H. P. Pepper, M.D., and J. H. Austin, M.D.

The report was simply a summary of the various metabolic studies which have been in pernicious anemia. Emphasis was laid upon such of these studies as tend to throw light upon the degree of hemolysis, inasmuch as these evidences are the only ones which help in determining whether a case of anemia would be benefited by splenectomy or not. It is the general belief that only such cases of anemia as show increased hemolysis should be splenectomized and evidences of this increased hemolysis can usually be shown chemically. *March* 23, 1916.

A Transparent Museum Preparation.

W. J. Crocker, V.M.D.

The specimen is that of a pig embryo made transparent by the following procedure:

1. Preparation of the object (removing scales, and hair, and injection).
2. Fixation.
3. Decalcification.
4. Bleaching (H_2O_2, either acid or weakly alkaline).
5. Washing.
6. Dehydration in different strengths of alcohol to 100 per cent.
7. Immersion in benzol.
8. Placing in end fluid (oil of wintergreen).
9. Evacuation to take out benzol and air.

Digitized by Google

For further details see the second edition of Dr. Werner Spalteholz's book, *Ueber das Durchsichtigmachen von Menschlichen und Tierischen Praparaten*, G. E. Stechert & Co., 129-133 W. 20th Street, New York. The specimen came from G. S. Shimadzu & Co., Kyoto, Japan. *April* 13, 1916.

Pigmentation of the Colon.

HERBERT FOX, M.D.

This monkey showed Pick's melanosis on the large intestine lying beneath the substantia propria and interpreted by this author as due to the action of tyrosinase. The interest in this finding is increased when one considers the high carbohydrate diet to which an occasional bowl of milk and an egg adds some protein. Such pigmentation is rare in the lower animals, near to man the usual deposits being either pseudomelanotic or splotches in, or in the vicinity of, lymphatics. *April* 13, 1916.

Various Methods for Determining the Trypanocidal Activity of Substances in Vitro and Their Relation to the Chemotherapy of Experimental Trypanosomiasis.[1]

JOHN A. KOLMER, M.D., JAY F. SCHAMBERG, M.D., AND GEORGE D. RAIZISS, PH.D.

(From the Dermatological Research Laboratories of the Philadelphia Polyclinic and College for Graduates in Medicine.)

CONCLUSIONS. 1. Trypanocidal tests *in vitro* have been found of distinct value in chemotherapeutic researches in experimental trypanosomiasis.

2. Substances exerting a profound trypanocidal activity *in vitro* are likely to prove trypanocidal *in vivo*, providing the drug is sufficiently non-toxic that it may be administered in adequate dosage.

3. With the combined *in vitro-vivo* method described herein, it has been found possible to detect the trypanocidal activity of new compounds which were without effect *in vivo* in amounts but slightly less than the sublethal dose.

4. By the methods described herein arsenobenzol or salvarsan has been shown to possess a high trypanocidal activity *in vitro*.

5. *In vitro* methods have also demonstrated a trypanocidal activity on the part of mercurials which is not apparent in the *in vivo* tests. *April* 13, 1916.

[1] Published in full in the Journal of Infectious Diseases, 1917, xx, 10 to 28.

Digitized by Google

Antigenic Properties of Tubercle Wax.[1]

BALDWIN LUCKE, M.D.

Tubercle wax is the name applied to fatty and waxy substance extracted from tubercle bacilli with fat solvents, such as alcohol, ether, benzol, chloroform, etc. The percentage of this substance that can be extracted varies according to the different strains of tubercle bacilli, their age, virulence, and media upon which they are grown, and upon solvents employed in extraction.

Tubercle wax used in this investigation was furnished by Dr. Rucker, of the Pennsylvania State Laboratories, and was prepared from both human and bovine bacilli grown upon bouillon and extracted with alcohol, ether, and hot benzol. About 20 to 22 per cent. of wax was thus obtained.

The object of this investigation was (1) to determine whether extracts of tubercle wax possessed any antigenic value in the serum diagnosis of tuberculosis; (2) to explain the reason for the frequent fixation of luetic serum with various antigens used in complement-fixation in tuberculosis. The method employed is essentially similar to that of the Wassermann reaction.

The antigen emulsion of tubercle wax was prepared by first dissolving it in ether and then adding normal saline. This antigen was titrated before each main test and its anticomplementary unit ascertained. One-third of this unit was employed. All sera were used in doses of 0.1 c.c. after inactivation for one-half hour at 55° C. Two hundred sera of normal, tuberculous, and luetic patients were tested.

The conclusions reached were: (1) tubercle wax antigen causes complement-deviation with a large percentage of sera possessing lipotropic properties (luetic sera); (2) these antigens also cause complement-deviation with a moderate percentage of presumably normal and tuberculous sera; (3) they appear to possess neither diagnostic nor prognostic value in the serum diagnosis of tuberculosis. *April* 13, 1916.

Primary Endothelioma of the Pleura.

ROBERT A. KEILTY, M.D.

Primary endothelioma of the pleura is relatively rare and from the literature occurs as a single tumor or as multiple nodules. Progressive loss of weight, dyspnea and fluid in the chest are the most common symptoms. The tumor shows an endothelial type of cell with epithelial groupings, hence often the name endothelial cancer.

[1] Published in full in the Journal of Immunology.

Digitized by Google

Clinically the case reported was of seventeen months' duration. The patient presented loss of weight, weakness, cough, expectoration, headache, vomiting, gastro-intestinal symptoms, chest signs of consolidation, *x*-ray shadow over the primary growth, metastases, and palpable lymph nodes, palpable liver with nodules, fixation of the vocal cords, negative sputum and Wassermann, and secondary anemia. The case terminated in a nephritis, cardiac failure, Jacksonian convulsions, and hemiplegia.

Pathologically there was one large primary mass arising from the pleura, composed of endothelial cells in various types and arrangements with extension to the lung, bronchial lymph glands, trachea and bronchi, and compression of the aorta. Metastases followed to the liver, kidney, lymph nodes, abdominal skin, right radius and brain, with erosion of the spinal bony column and fracture of a rib.

April 13, 1916.

A Final Report on the Cultivation of the Tubercle Bacilli from the Sputum by the Method of Petroff.[1]

ROBERT A. KEILTY, M.D.

The method of Petroff offers an opportunity for the isolation of the tubercle bacillus in pure culture from the sputum. The method is available for the demonstration of the tubercle bacillus when otherwise not demonstrable. The method is easy and rapid, but requires detail and constant observation. The plain egg-veal medium is the best medium thus far devised for the luxuriant growth of the tubercle bacillus. The method supersedes antiformin, having all its good qualities and others in addition. It is possible by applying the method to isolate the tubercle bacillus from a swab of the throat. By using the digestive powers of sodium hydroxide it is possible to demonstrate more readily the presence of the tubercle bacillus in tissue, thus saving time on animal inoculation. Finally, if positive results are obtained from an otherwise negative case the method opens up one more avenue of diagnosis.

April 13, 1916.

The Active and Passive Immunity Against Diphtheria, Including a Discussion of the Schick Test.[2]

WILLIAM H. PARK, M.D.

April 27, 1916.

[1] Published in the Journal of Experimental Medicine, vol. xxiv, No. 1.
[2] Title of Address delivered at the Annual Conversational Meeting.

Digitized by Google

Hypernephroma with Multiple Metastases.

B. LUCKE, M.D., AND E. LINDAUER, M.D.

May 11, 1916.

Osteoma of the Falx Cerebri.

GEORGE E. PRICE, M.D.

May 11, 1916.

Sarcoma of the Right Frontal Lobe.

GEORGE E. PRICE, M.D.

May 11, 1916.

Exhibition of Bladder and Prostatic Pathology.

ALEXANDER RANDALL, M.D.

Toward the end of last year I started examining all bladders, prostates, urethras, and seminal vesicles as they came to autopsy at the Philadelphia General Hospital. I had several problems in view, but especially wished to simply examine for gross lesions of interest all specimens irrespective of age or cause of death. Thirty-three per cent. of these have shown gross pathological changes. To date there have been 118 specimens examined, varying as to age from nineteen to seventy-nine years, and it is my desire to show you tonight by lantern slides, drawings, and specimens, some of the lesions that have been encountered, some of the problems that have yet to be studied, at the same time putting forward an earnest plea that more attention be given these parts at the postmortem.

There have been found 39 cases of gross lesions of either the vesical orifice, the prostate, the posterior urethra, or the seminal vesicals, and this does not include a great many cases where trabeculation, congestion, or even inflammation of the bladder or urethra was present, due to conditions in the upper urinary tract and unassociated with gross lesions of the lower urinary tract.

The conditions found may be grouped and classified as follows:

General hypertrophy of prostate (right, left and median lobes)	5 cases
Hypertrophy of the median lobe only	7 "
Atrophy of the prostate	1 "
Dilated vesical orifice (case of tabes)	1 "
Diseased posterior urethra	5 "
Median bar (large)	5 "
Median bar (small)	15 "
Tuberculosis	3 "
Calculi in the prostate (54 cases examined, or 20 per cent.)	11 "

May 11, 1916.

Digitized by Google

Leukocytes in Viridans Endocarditis and the Influence of Nuclein.

HERBERT FOX, M.D., AND F. B. LYNCH, M.D.

May 11, 1916.

Effect of Nuclein on the Leukocytes of Dogs.

HERBERT FOX, M.D., AND F. B. LYNCH, M.D.

May 11, 1916.

Visceral Amebiasis, with Report of a Case.

A. J. RUBENSTONE, M.D.

My case was a Russian man, aged forty-nine years, who complained of pain in the right buttock and dyspnea on exertion. He had lived in southern Russia until fourteen years ago, when he came directly to this city.

Physical examination revealed a fluctuating mass in the right buttock and upon deep puncture of the mass six ounces of fluid were withdrawn. It was yellowish brown, moderately viscid, and very turbid. Examination of fresh specimens showed microscopically some polynuclear and mononuclear leukocytes, much cellular débris, and fragmented red cells as well as larger cells, many of them in motion. These cells ranged from 20 to 50 microns in diameter, and showed typical ameboid movement, very active in some. They consisted of a clear ectosarc, glassy in appearance, and a granular endosarc, in which could be seen small grayish particles and occasionally fragments of or whole red blood cells as well as one or more vacuoles. The pseudopodia were blunt and broad and somewhat elongated; very few cells exhibited more than one projection at a time. Mobility was marked in a great many of them and sluggishness in a few. Some encysted forms were present. No distinct nucleus was evident in most of the cells.

The parasite found in these lesions conforms in nearly all characteristics to the Ameba hystolytica (Schaudin). In the absence of any other demonstrable etiological factor we conclude that this parsite was the cause of the production of these lesions. The unique situation of the abscesses leads us to think that the distribution of these parasites was hematogenous. We can only speculate as to the original focus of infection, remembering the condition of the patient's mouth. *May* 11, 1916.

Digitized by Google

Thrombosis of Aorta and Iliacs in a Horse.

W. J. Crocker, V.M.D.

The thrombus occludes the terminal six inches of the aorta, both internal and external iliac arteries, and the right femoral artery. The circulation in the hindquarters was so reduced that they were cold to the touch. Upon exercise lack of blood supply induced weakness, lameness, and finally paralysis of the posterior part of the body. The thrombus usually follows an endarteritis or is due to the lodging of an embolus, derived from a thrombus in the anterior mesenteric artery which is very common and induced by embryos of the Sclerostomum bidentatum. *May* 25, 1916.

A Device for Protection Against the Tubercle Bacilli.[1]

Robert A. Keilty, M.D.

(From the McManes Laboratory of Pathology, University of Pennsylvania.)

Numerous devices have been advocated from time to time to overcome the "jumping" of the tubercle bacillus as well as other material from a platinum loop while it is being flamed. A mass may jump at least fifteen inches from the flame, unless one is very cautious. It is possible to overcome this fault by first gently heating and then bringing the needle into the flame, but this is time-consuming where one has considerable work at hand. I lay claim to no originality for this device because, had I the time, I am sure I might find a similar contrivance reported previously. My idea is simply to call attention to this, since in many laboratories working with the tubercle bacillus no protection is used, and undoubtedly there is an element of danger.

The tube is made of Russian iron, has a bottom with a hole just large enough to admit the burner of a Bunsen, is high enough to cover the flame, and is mounted on three legs long enough easily to work the pilot light. The lumen of the tube is small, so that the sides become fairly hot. This is an advantage, since many of the masses will adhere to the inner side of the tube and eventually be consumed. Bacteria which do not adhere will drop to the bottom. In use the platinum loop may be immediately plunged into the flame. Any masses which jump will be caught. After one is through, the Bunsen is to be removed and the inside of the tube thoroughly flamed or otherwise sterilized. *May* 25, 1916.

[1] Published in full in the New York Medical Journal for June 3, 1916.

Digitized by Google

A Study of Chloride Retention in Nephritis and Eclampsia.

C. C. WOLFERTH, M.D.

May 25, 1916.

Clinical Studies of Acidosis.

J. HAROLD AUSTIN, M.D., AND LEON JONAS, M.D.

(From the William Pepper Laboratory of Clinical Medicine, University of Pennsylvania.)

1. In the new methods for studying acidosis directly from the blood we have a means of investigation that constitutes a distinct advance upon our previous methods.

2. As criteria of the supply of "buffer substance" in the blood the carbon dioxide capacity of the plasma (Van Slyke, Stillman, and Cullen method) the hydrogen-ion concentration of the serum (Levy, Rowntree, and Marriott method) and the alveolar air (Plesch-Higgins method) give results that are in general parallel. The first of these is the most sensitive of the three and gives much more satisfactory duplicates than does the alveolar-air determination. It affords a simple and quick method of determining the presence and degree of acidosis.

3. In using the method for the CO_2 capacity of the plasma, and presumably in any method intended to measure directly or indirectly the alkalinity of the plasma, the CO_2 concentration of the whole blood must be kept unchanged or brought to a standard tension while centrifuging and separating the plasma from the cells.

4. Asphyxia or any condition of high CO_2 tension in the blood *in vivo* raises the CO_2 capacity of the plasma if the latter is separated by the paraffin-oil method, and may interfere with the recognition of a slight acidosis. This may be overcome by saturating the whole blood at a standard CO_2 tension before centrifuging and maintaining this tension until the plasma is pipetted off.

5. By the Van Slyke method the normal CO_2 capacity of the plasma reduced to 0°, 760 mm. pressure, and correcting for vapor tension, appears to be about 65 to 80 volumes per cent. This is slightly reduced in arteriosclerotic conditions and moderately to markedly reduced in diabetes and nephritis, especially in the advanced stages.

6. After ether anesthesia there is a depression of the CO_2 capacity of the plasma of from 2 to 20 volumes per cent. This depression is proportional to the duration of the anesthesia. The lowest figure observed was 47. This reduction is present and probably maximal at the close of the anesthesia, and apparently remains

Digitized by Google

little altered for at least five hours. A single injection of two pints of a 5 per cent. glucose solution per rectum at the close of the anesthesia does not lessen the reduction in the CO_2 capacity during the next five hours. *May* 25, 1916.

A Study of the Normal Bacterial Flora of Postage Stamps.[1]

ROBERT A. KEILTY, M.D., AND MR. PHILIP D. MCMASTER.

CONCLUSIONS. 1. A study of fifty stamps obtained from as many different sources, clean, dirty and indifferent, showed bacteria in every instance except two.

2. With the possible exception of two cases no organism pathogenic in type was encountered.

3. Aside from hygienic reasons it is dangerous to lick postage stamps, on the ground that the stamps are bacteria-laden and under favorable conditions might easily convey pathogenic types, especially colon, diphtheria, and tubercle bacillus.

4. We would therefore advocate a movement to have installed in all places dispensing postage stamps a moistening device of some type. This movement could be started with beneficent results in the post-offices of the United States Government.

May 25, 1916.

Cretinism in Wolves.

HERBERT FOX, M.D.

Demonstration of representatives of two litters of cretin wolves, from a healthy mother fathered by a goiter-bearing, well-developed male wolf in the first litter and a healthy, well-developed, male without cervical swelling for the second litter. Most, but not all, of the young wolves show some thyroid abnormality. They all show the graceful bony construction of cretinism as contrasted with the skeletons of chondrodystrophy and osteogenesis imperfecta.

October 12, 1916.

Cesarean Section and Panhysterectomy for Carcinoma of the Cervix.

E. B. PIPER, M.D.

Specimen is that of a uterus with adnexia showing carcinoma of the cervix. The patient was seen at about the fifth month of pregnancy, with a history of hemorrhage.

[1] Published in full in the New York Medical Record, July 22, 1916.

Digitized by Google

Examination showed a typical carcinomatous cervix which bled easily. It was determined to allow the patient to go to term or nearly so. This idea was carried out, and two weeks before term a living child was delivered by hysterotomy and a panhysterectomy done. The subsequent treatment was application of radium to vaginal vault, which is clearing up some metastases, and the patient is making a satisfactory recovery. *October* 12, 1916.

The Relation o the Bronchisepticin Skin Reaction to Immunity In Canine Distemper Including the Bactericidal Action of Dog Serum for B. Bronchisepticus.[1]

JOHN A. KOLMER, M.D., TOITSU MATSUNAMI, M.D., AND MALCOLM J. HARKINS, V.M.D.

(From the McManes Laboratory of Experimental Pathology of the University of Pennsylvania, Philadelphia, and the H. K. Mulford Co. Laboratories, Glenolden, Pa.)

1. Anaphylactic skin tests with a polyvalent antigen of washed and heat-killed B. bronchisepticus (Ferry-McGowan) indicate that a large percentage of dogs are hypersensitive to the protein of this bacillus.

2. Dogs known to have had distemper yielded the highest percentage of positive reactions; a large proportion of apparently normal dogs reacted in a positive manner when tested soon after admission to the animal house, but there was no means of learning what proportion of these animals had had the disease.

3. Bronchisepticin intracutaneous reactions are probably specific reactions due to hypersensitiveness to the protein of B. bronchisepticus; similar tests with an emulsion of typhoid bacilli yielded negative reactions.

4. The sera of normal dogs, those suffering with distemper and those convalescent from this infection, possess slight or no bactericidal activity over B. bronchisepticus as measured by tests *in vitro*.

5. There is no relation between the results of bronchisepticin anaphylactic reactions and the bactericidal power of the serum. The sera of dogs yielding positive anaphylactic reactions in the skin did not appear to have an appreciable increased bactericidal value.

6. Agglutinins and complement-fixing antibodies for B. bronchisepticus appear to be increased to some extent in distemper. Normal dog serum contains agglutinin for this bacillus and yields

[1] Printed in full in the Journal of Immunology, October, 1916, vol. i, No. 5.

Digitized by Google

non-specific complement-fixation reactions so that both procedures possess but little practical value in the diagnosis of distemper. In our experiments we were unable to detect a relationship between the agglutinins and bacteriolysins on the one hand and the skin reactions on the other.

7. Evidence at hand indicates that dogs yielding positive bronchisepticin reactions are still susceptible to canine distemper.

October 12, 1916.

Experiments with the Bloch Method for Smegma Bacilli.

F. G. HARRISON, M.D.

The question arose whether the Bloch method of injecting guinea-pigs would be reliable for suspected tuberculous bacilli in the urine if smegma bacilli were present and an attempt was made in a short series of experiments to have the inguinal glands take up smegma bacilli, which are practically morphologically identical with tuberculous bacilli.

An emulsion of smegma bacilli was made and 2 c.c. were injected subcutaneously in the thigh after the inguinal glands had been bruised.

The pigs were killed on the second, third, fourth, fifth, sixth, eighth, tenth, fourteenth, and thirtieth day after inoculation. While some of the pigs lost weight, none appeared sick. There were no signs of inflammation nor enlargement of the glands, and after excision no smegma bacilli were found. Two of the series developed localized abscesses at the site of inoculation, from which smegma bacilli were recovered.

The controls were carried out with an emulsion of tubercle bacilli, which were recovered from the inguinal glands.

October 12, 1916.

A Method of Obtaining Duplicate Reconstructions from the One Series of Wax Plates.

FRED D. WEIDMAN, M.D.

Ordinarily reconstructions are made by outlining the projected histological serial sections upon wax sheets, cutting them out and superimposing. That part of the sheet which is left is usually discarded, but by the author's scheme these "negatives" are superimposed as in the case of the "positives" and the resultant cavity filled with plaster of Paris. When it has solidified the whole mass is warmed until the wax encasement runs off, leaving a duplicate

Digitized by Google

reconstruction, this time in plaster. The duplicate is really more durable than its wax counterpart, certainly in tropical countries and in case of fires. Several precautions must be taken, for which see description in full in *New York Medical Journal.*

October 12, 1916.

Observations on the Pathology of Early Hanot's Cirrhosis and of Weil's Disease.

J. H. AUSTIN, M.D., AND A. C. WOOD, M.D.

The first case described was an extremely acute infectious cholangitis with high fever, polymorphonuclear leukopenia, extreme toxemia, and intense jaundice, which terminated fatally.

The histological examination of the liver showed the following picture:

A very slight, practically negligible degree of cirrhosis. Marked fatty infiltration of many of the liver cells, with nuclei quite normal. Scattered areas which, taken together, make up about one-third of the total section, in which the bile capillaries are distended with bile, and around these the liver cells are filled with bile pigment, exhibit fatty degeneration, with pale nuclei or occasionally actual necrosis. Between these degenerated areas the liver cells are quite normal or exhibit the fatty infiltration referred to. The large bile ducts are not distended and show no change other than a slight cloudy swelling of the epithelium and the presence of eosinophilic granules in the lumens.

The picture suggests a widespread infectious cholangitis of the finer biliary capillaries without much involvement of the larger ducts, and does not suggest phosphorus poisoning or any condition arising primarily in the liver cells themselves nor a gross obstruction of the lower bile passages, as for instance by stone.

The second case was one of extreme hepatic enlargement of one year's duration associated with jaundice and low-grade irregular fever. For the purpose of preparing vaccines a small piece of the liver tissue was removed and cultures were made from this and from the bile taken from the gall-bladder.

Histological examination of the liver tissue removed at operation showed the following picture: Cloudy swelling of the liver cells and of the epithelium of the bile ducts. Marked cellular infiltration, chiefly lymphoid, but with also a very considerable proportion of polymorphonuclears, most pronounced in the portal spaces around the bile ducts, but also in a very considerable degree throughout the entire lobule where the infiltrating cells are seen in linear strands. Little if any fibrous tissue formation.

Digitized by Google

The condition might be interpreted as a Hanot's cirrhosis, but the marked predominance of the infiltration about the bile ducts suggests a biliary cirrhosis subsequent to a low-grade cholangitis. There is no evidence of gross obstruction in the lower biliary passages, however. The large number of polymorphonuclears is of special interest. *October* 12, 1916.

History and Probable Nature of the Virus of Poliomyelitis.

PAUL A. LEWIS, M.D.

October 26, 1916.

The Pathology of Poliomyelitis and Its Relation to the Virus.

GEO. E. PRICE, M.D.

October 26, 1916.

The Use of Normal and Immune Serum in the Treatment of Poliomyelitis.

C. Y. WHITE, M.D., AND J. D. ARONSON, M.D.

October 26, 1916.

Acidosis.[1]

LAURENCE J. HENDERSON, M.D.

November 9, 1916.

Unilateral Renal Tuberculosis with Thickening of the Pelvic Ureter.

J. LEON HERMAN, M.D.

Specimen of left kidney removed from an Italian woman, aged twenty-four years. Capsule is thickened and adherent; surface is roughened and studded on its dorsal surface with small whitish pin-point-sized dots. The cortex is thickened and studded with similar though larger spots. At the junction of the cortical and medullary portions there are several small cavities. The pelvis of the kidney is much thickened. The ureter is thickened and its mucosa lacerated in places. Sections from various portions of the kidney, from the ureter and from its pelvis, show typical tubercu-

[1] Title of the Annual Samuel D. Gross Lecture.

Digitized by Google

lous inflammation. The specimen was removed by Dr. Baldwin October 19, 1916. Important clinical findings were thickened, left ureter easily palpable in the vault of the vagina; large kidney demonstrable by *x*-ray examination. Retardation of indigo-carmine output and the kidney on the right side is normal and is demonstrable by functional tests. *November* 23, 1916.

Specimen of Ruptured Right Kidney.

J. LEON HERMAN, M.D.

Specimen removed from a boy, aged seven years, who had been run over by a wagon. At operation the abdomen was found filled with fluid. There were two large tears in the mesentery and one in the transverse mesal colon. The posterior parietal peritoneum on the right side was ballooned forward over the region of the right kidney. This was incised and a large clot of blood removed. The kidney was found to be torn loose from all its attachments, including the ureter. It was lacerated, one large piece representing the lower pole lying free in the mass of clotted blood.

November 23, 1916.

Tuberculosis of the Kidney with Profuse Hemorrhage.

F. E. KEENE, M.D.

This specimen of renal tuberculosis is of clinical interest because it presents a type of lesion not commonly seen in which profuse hematuria is more or less characteristic. Renal hemorrhage may be associated with the congestion of an early tuberculous nephritis, but is not a common symptom of the more advanced stages as represented by the usual cavernous and indurating types. This kidney was removed from a patient, aged twenty-three years, whose chief symptom was frequent and painful urination of several months' duration. On two occasions profuse hematuria occurred, lasting for a day or two and then completely disappearing. During the period of bleeding the patient suffered severe colicky pain in the left kidney region. Cystoscopic examination showed a left ureteral orifice presenting changes typical of tuberculosis, with normal anatomical and functional findings on the opposite side. The left kidney was removed and on opening it numerous nests of tubercles were seen scattered through the renal cortex, and at one papilla there was an ulceration about 1.5 cm. in width and 1 cm. in depth.

This type of lesion has been described by Israel, and is known as

Digitized by Google

tuberculous papillitis. According to his conception, the tubercle bacilli pass through the glomeruli and are excreted, passing into the straight tubules and finding lodgment at the papilla, where they produce ulceration. Each renal papilla is surrounded by a network of veins, and erosion into these blood channels is the cause of the profuse hemorrhage so characteristic of this lesion.

November 23, 1916.

Two Cases of Papilloma of the Bladder.

ROBERT A. KEILTY, M.D.

The first case is a clinical one. In November, 1915, the patient had typical symptoms, and by cystoscopic examination it was found that he had a papilliferous tumor just at the orifice of the left ureter, from the center of which a bloodvessel was spurting. This was treated by fulguration by the late Dr. Uhle. At the end of a week, examination revealed a small tab remaining which received another treatment. On April 1, 1916, it was noted that a small scar had resulted, and to date there has been no recurrence.

The second case was discovered accidentally at autopsy. The patient, A. M., had been an inmate of the insane department of Blockley since 1893. He had an uneventful course, with chronic constipation as his only complaint. At autopsy the bladder was enormously distended with hydro-ureter and hydronephrosis. This was seen to be due to a papilliferous growth at the urethral orifice of the bladder. The tumor had arisen from the urethral mucosa and had grown down into the lumen of the urethra, acting like a stopper. *November* 23, 1916.

An Early Case of Eclampsia, with Autopsy.

ROBERT A. KEILTY, M.D., AND S. PAUL TAYLOR.

No attempt is made in the paper to bring out etiological factors, but the more important morphological changes which seemed to have a direct bearing, and in this way possibly suggest avenues for future study.

In a summary of the case the following points stand out: A young woman apparently healthy, aside from the possibility of syphilis with early arteriocardiorenal changes, gave birth to normal twins. She developed a toxemia almost immediately and died in sixty-five hours. Whatever might have been the stimulating factor, the liver above all else was involved with extensive vascular, degenerative, and necrotic changes. The heart and kidney suf-

Digitized by Google

fered degenerative faults secondarily: The kidney may have been involved and was to a slight extent previously, but in comparison to the severity of the liver was not in this case at least the important factor. Hemorrhages into the adrenal and transudation of the peritoneum, with hemolysis accompanied by early splenic reaction, complete the picture. *November* 23, 1916.

Disproportionate Right Ventricular Preponderance, with Electrocardiographic Evidence.

EDWARD B. KRUMBHAAR, M.D.

The heart is from a boy (J. P.), aged seventeen years, who died at the University Hospital this year suffering from chronic mitral endocarditis with extreme stenosis. It is of interest both from the pathological point of view, on account of the disproportionate size of the right ventricle and the atrophied left ventricle, and also from the clinical point of view, as demonstrating the superior value of the electrocardiograph over other methods of diagnosis in estimating the size of the two ventricles. On inspection, percussion, and *x*-ray examination the evidence pointed chiefly to left ventricular hypertrophy: the cardiac shadow and dulness were chiefly increased to the left, and there was a prominent, positive apex beat in the sixth space at the midclavicular line. Nevertheless, at autopsy the right ventricle was found to be tremendously hypertrophied, weighing over 300 grams; whereas the left ventricle, due to the extreme mitral stenosis, was atrophied and weighed only 120 grams. In spite of the fact that the apex beat was protruded instead of retracted it was unquestionably caused by the right ventricle. *November* 23, 1916.

Congenital Aneurysmal Dilatation of Ductus Botalli.

D. M. DRY, M.D.

Baby E., male, aged three days, one of twins born spontaneously in the Jefferson Hospital Meternity Department, service of Prof. E. P. Davis. The child was undersized and weak, but there was no external evidence of faulty development; weakness progressed until death occurred; diagnosis, general debility. The other twin, a female, was normal and at present is living, strong and well. The mother's history is negative. Evidence of lues lacking. Wassermann test not made.

Digitized by Google

Necropsy, twenty hours after death. Between the pulmonary artery and aorta a short distance above their exit from the ventricles was an ovoid, fluctuating, cystic mass the size of a large cherry. On incision it contained a small amount of recent free blood clot. At each end of the mass was an opening communicating with the aorta on the inferior aspect of the arch, on the one hand, and the pulmonary artery above and to the inner side of the left branch on the other. Wall of the cystic mass is very thin, smooth, and regular. Greatest diameter of mass, 11 mm.; aortic orifice, 5 mm.; pulmonic orifice, 3 mm. Heart and great vessels otherwise normal. Other autopsy findings irrelevant. Histologically the wall was made up of a thin layer of muscle and practically no elastica.

This case showed a central dilated portion; contraction at both extremities most marked at pulmonic end; no valvular fold at aortic end, as is often seen; no evidence of thrombus formation within. The condition of lungs, pulmonary artery and aorta was such as to cause only normal alterations in blood-pressure.

The condition has been considered as aneurysmal, and all the possible changes of an aneurysm as being of distinct clinical interest and of vital importance to the patient. *November* 23, 1916.

A Pathologic Anatomic Analysis of Three Hundred Aneurysms Recorded in Thirteen Thousand Consecutive Autopsies.

BALDWIN LUCKE, M.D.

November 23, 1916.

Fibroid Tumor Complicating Pregnancy.

B. M. ANSPACH, M.D., AND F. B. BLOCK, M.D.

The specimen consists of a five months' pregnant uterus with the fetus *in situ* and a fibromyoma about the size of an orange growing in the lower part of the anterior wall on the left side. This complication of pregnancy is rather common, but each case is a law unto itself when treatment is considered. In the case in question the tumor was so low that complications during labor were feared if the patient were allowed to go to term. On that account a supravaginal hysterectomy was performed, conserving both ovaries. Myomectomy could not be performed, as the growth involved the uterine wall as far in as the fetal membranes.

December 14, 1916.

Digitized by Google

Dermoid Cyst Complicating Pregnancy.

F. B. BLOCK, M.D.

The frequency of ovarian tumors during pregnancy has been stated to be 1 in 3000 cases. Of all such cases 23 per cent. are embryomata. In 80 per cent. of the cases of ovarian cyst complicating pregnancy torsion occurs; in 33 per cent. serious consequences ensue if the patient is allowed to go to term; in 20 per cent. of the cases the patient will miscarry after operation. The present case was diagnosed as ovarian cyst before operation, which was performed for the relief of pain. On opening the abdomen, in addition to a five months' pregnant uterus, there was found a dermoid cyst of the right ovary which had twisted once on its pedicle. Subsequent to operation the patient was kept under the influence of morphin for over two days in order to avoid uterine contractions. The patient did not miscarry, and the convalescence was uneventful. *December* 14, 1916.

The Effect of Certain Drugs upon Skin Reactions.[1]

JOHN A. KOLMER, M.D., SAMUEL L. IMMERMAN, M.D., TOITSU MATSUNAMI, M.D., AND CHARLES M. MONTGOMERY, M.D.

(From the McManes Laboratory of Experimental Pathology of the University of Pennsylvania, Philadelphia, Pa.)

SUMMARY. 1. The iodides, and particularly potassium iodide, were found to influence the luetin and prodigiosus intracutaneous tests to a marked extent. Normal non-syphilitic persons, reacting negatively in the luetin test, may show marked reactions when tested after the oral administration of 60 or more grains of potassium iodide.

2. The bromides of potassium and sodium in the same dosage were found to have a similar but less marked influence.

3. The chlorides of potassium and ammonium in the same dosage were found to influence the prodigiosin reactions but not the luetin reactions except to a very slight extent.

4. The administration of the protiodide of mercury influenced the luetin reaction to some extent.

5. It is probable that the administration of larger doses of these drugs would exert a more marked influence upon skin reactions.

6. Ether and chloroform anesthesia did not appear to influence skin reactions.

[1] Printed in full in the Journal of Laboratory and Clinical Medicine, March, 1917.

Digitized by Google

7. Substances most likely to excite inflammatory reactions in the skin appear to be most readily influenced by the iodides and to some extent by the bromides; intracutaneous tests with agar-agar, prodigiosin, and ordinary luetin were more readily influenced by these drugs than the reactions following the injection of a luetin of washed spirochetes and free of culture medium.

8. Cutaneous tests are not as readily influenced by these drugs as intracutaneous tests.

9. Conjunctival tests among normal rabbits to tuberculin were apparently not influenced.

10. Cutaneous and intracutaneous reactions to tuberculin among persons reacting positively to both, appear to be rendered more extensive by potassium iodide and to a lesser extent by potassium bromide.

11. Anaphylactic reactions to luetin in syphilitic persons appear to be rendered more extensive by potassium iodide and potassium bromide.

12. The oral administration of potassium iodide, and to a lesser extent of potassium bromide, increased the phagocytic power of the blood serum for B. prodigiosus; the increased severity of skin reactions in persons taking these drugs may be due to heightened leukocytic infiltration and phagocytosis about the injected material or to an increase of tryptic activity through the saturation of fatty acid radicals according to the hypothesis of Jobling and Petersen.

13. Physicians should very carefully rule out the possible influence of these drugs before conducting skin reactions.

14. It is probable that these drugs have influenced the luetin reactions as clinically applied and have been responsible in part for the divergent results observed and reported.

Classification of Leukocytes: A Review.

A. G. Ellis, M.D.

The writer summarized the views of hematologists in naming the leukocytes. The chief difference of opinion is regarding the large mononuclear and transitional. Many believe these are simply forms of one-cell type, but there is wide variance of theories as to their origin. Until these theories are cystallized the adding of new names appears to make for confusion rather than clearness. Large lymphocyte, or perhaps better, large mononuclear (including the transitional), should suffice until more definite knowledge is obtained.

December 14, 1916.

Digitized by Google

Four Types of Transient Heart-block Studied with the Electrocardiograph.

EDWARD B. KRUMBHAAR, M.D.

Cases representing four different types of transient heart-block were described and their electrocardiograms analyzed and discussed:

(*a*) Transient partial auriculoventriculor heart-block of myocardial origin, occurring during an exacerbation of acute rheumatic carditis, varying with the degree of arthritis, yet responding to atropin. The block in this case was probably due to involvement of the special conductive tissue in an acute rheumatic myocarditis.

(*b*) Transient complete auriculoventricular heart-block, brought on by extremely small doses of digitalis, and temporarily relievable by atropin. Although the digitalis was the determining cause of the heart-block, a fibrosis of the bundle probably contributed to its production.

(*c*) The development during a period of over two years of block in the right branch of His's bundle in an old man suffering with arteriosclerosis, chronic myocarditis, and anginoid symptoms.

(*d*) Transient periods of prolongation of the *P-R* interval without adequate cause in a healthy young adult male. He was also subject to paroxysmal tachycardia of auricular origin, occurring independently of the state of conduction of the conductive system.

In neither of the two cases that have since died (*a* and *c*) was an autopsy obtainable.

December 14, 1916.

Digitized by Google

Digitized by Google

INDEX TO TITLES.

A

ABDERHALDEN Test, The Bacteriological Aspect of
D. Rivas and A. C. Buckley 12
Aberrant Cerebellar Tissue in Occipital Bone
Fred D. Weidman 2
Acidosis
Lawrence J. Henderson 46
Acidosis, Clinical Studies of
J. Harold Austin and Leon Jonas 41
Adrenals Showing Lesions Found in Pellagra
W. M. L. Coplin 30
Amebiasis, Visceral, with Report of a Case
A. J. Rubenstone 39
Amebic Dysentery
Thomas McCrae and D. M. Dry 25
Amyloid Kidney, Unusual Specimen of
Baldwin Lucke 5
Aneurysms, A Pathologic Anatomic Analysis of Three Hundred, Recorded in Thirteen Thousand Consecutive Autopsies
Baldwin Lucke 50
Aneurysms, Multiple Large
Baldwin Lucke and W. L. Francis 32

B

BENCE-JONES Proteinuria, Studies In
A. E. Taylor and C. W. Miller 17
Bence-Jones Protein, The Clinical Significance of
T. G. Schnabel 18
Bladder and Prostate Pathology, Exhibition of
Alexander Randall 38
Bloch Method for the Smegma Bacilli, Experiments with the
F. G. Harrison 44
Blood, Fate of Large Quantities of, Introduced into the Peritoneal Cavity
J. E. Sweet and M. M. Peet 21
Bronchisepticin Skin Reaction to Immunity in Canine Distemper Including the Bactericidal Action of Dog Serum for B. Bronchisepticus
John A. Kolmer, Toitsu Matsunami and Malcolm J. Harkins . . . 43

Digitized by Google

C

CALCIUM and Parathyroid Medication in Tuberculous Guinea-pigs, Further Report upon
R. C. Rosenberger and P. S. Pelouze 29
Carcinoma of the Cervix, Cesarean Section and Panhysterectomy for
E. B. Piper 42
Carcinoma of Lung Simulating Chorio-epithelioma
A. G. Ellis 25
Carcinomatous Degeneration of Papilloma of the Cecum
John Speese 15
Cardiac Formula for the Relative Measurements of the Valvular Orifices
Robert A. Keilty 9
Chemotherapy of Experimental Trypanosomiasis, The Numeric Relationships of Infection to
John A. Kolmer, Jay F. Schamberg and Geo. D. Raiziss 10
Chemotherapy of Experimental Trypanosomiasis, Various Methods for Determining the Trypanocidal Activity of Substances in Vitro and Their Relation to
John A. Kolmer, Jay F. Schamberg and Geo. D. Raiziss 35
Chloride Retention in Nephritis and Eclampsia
C. C. Wolferth 41
Chloride Retention, The Clinical Importance of
C. C. Wolferth 19
Chloride Retention without Edema; Report of a Probable Case
O. H. P. Pepper 18
Cholesteatoma Basis Cerebri
B. H. Lucke and R. H. Landon 6
Cholesterol Content of the Serum in Gall-bladder Disease
Martin E. Rehfuss and P. B. Hawk 28
Chondroma of the Pelvis
B. H. Lucke and Joseph McIver 7
Cretinism in Wolves
Herbert Fox 42
Cysts, Congenital Vaginal
F. E. Keene 31

D

DIPHTHERIA, The Active and Passive Immunity against, and Discussion of the Schick Test
William H. Park 37
Diverticulum of Esophagus
E. D. Funk 27
Ductus Botalli, Congenital Aneurysmal Dilatation of
David M. Dry 49

E

ECLAMPSIA, with Autopsy, An Early Case of
Robert A. Keilty and S. Paul Taylor 48
Endothelioma, Primary, of the Pleura
Robert A. Keilty 36

Digitized by Google

F

FATTY Tumor of Mesentery Causing Intestinal Obstruction
George M. Dorrance 17
Fibro-adenorhabdomyomatous Mesothelioma of the Kidney
Robert A. Keilty 8
Foreign Body (Roofing Nail) in Right Bronchus for Two and a Half Years
E. D. Funk 26
Formation of Specific Proteoclastic Ferments in the Blood in Response to the Parenteral Introduction of Foreign Proteins
Alonzo E. Taylor and Florence Hulton 23
Fragmentation of the Ovum within the Graafian Follicle
William H. F. Addison 1

G

GLIOMA of Brain, Giant-cell
A. G. Ellis 25
Gliomatous Tumor of the Brain
Alfred Gordon 16

H

HANOT'S Cirrhosis and Weil's Disease, Observations on the Pathology of
J. H. Austin and A. C. Wood 45
Heart-block, Transient, Four Types Studied with Electrocardiograph
Edward B. Krumbhaar 53
Hemoglobinometer, Clinical
Herbert Haessler and Harry S. Newcomer 19
Hemorrhage of Adrenal, Massive, in Adult, aged Sixty-four Years
Fred D. Weidman 3
Hemothorax Due to Ruptured Aortic Aneurysm
J. Parsons Shaeffer and E. H. Funk 30
Hydrocephalus the Result of Cyst of the Cerebellum
Robert A. Keilty 8
Hydrochloric Acid as a Decolorizing Agent for the Tubercle Bacillus
Robert A. Keilty 9
Hydrops Tubæ Profluens
F. B. Block and Thomas H. Llewellyn 16
Hypernephroma of the Lung Secondary to Hypernephroma of the Adrenals
A. C. Morgan and D. M. Dry 26
Hypernephroma with Multiple Metastases
B. Lucke and E. Lindauer 38
Hyperplastic Bone Formation under Old Mammary Operative Site
Fred D. Weidman 5

I

ILLUSTRATION as Applied to Medical Works, Various Methods of
Erwin F. Faber 11

Digitized by Google

K

KIDNEY, Single
J. Parsons Schaeffer and E. H. Funk 30
Kidney, Specimen of Ruptured Right
J. Leon Herman 47

L

LEATHER-BOTTLE Descending Colon, Sigmoid and Rectum
Robert A. Keilty 10
Lessons of the War on the High Cost and High Plane of Living
Alonzo E. Taylor 1
Leukocytes, Classification of
A. G. Ellis 52
Leukocytes in Viridans Endocarditis and the Influence of Nuclein
Herbert Fox and F. B. Lynch 39

M

MESENTERIC Thrombosis, The Result of Arteriosclerosis with Terminal Peritonitis, Death at the Age of Twenty-two from
Fred D. Weidman and Richard A. Kern 4
Method of Obtaining Duplicate Reconstructions from the One Series of Wax Plates
Fred D. Weidman 44
Myxosarcoma of the Mesentery
John Speese 14

N

NEPHROLITHIASIS of a Cow
Baldwin Lucke 6
Nuclein, Effect of, on the Leukocytes of Dogs
Herbert Fox and F. B. Lynch 39

O

OBSERVATIONS on the Influence of Angle of Section on Measurements of Cortex Depth and on the Cyto-architectonic Picture
Samuel T. Orton 24
Odontomas
Charles N. Bonney and A. G. Ellis 27
Osteoma of the Falx Cerebri
George E. Price 38
Ovarian Cysts, Preliminary Report upon the Toxicity of the Contents of
J. T. Leary, H. J. Hartz, and P. B. Hawk 33

Digitized by Google

P

PANCREASES, Accessary, (Two) in Wall of Jejunum
Fred D. Weidman 2
Papillary Carcinoma of the Stomach
John Speese 13
Papilloma of the Bladder, Two Cases of
Robert A. Keilty 48
Parasitic Skin Diseases and Their Possible Significance, Differential Blood Picture in
Albert Strickler 20
Pigmentation of the Colon
Herbert Fox 35
Pleural Effusion, Massive
J. Parsons Schaeffer and E. H. Funk 30
Poliomyelitis, The Pathology of, and Its Relation to the Virus
George E. Price 46
Poliomyelitis, The Use of Normal and Immune Serum in the Treatment of
C. Y. White and J. D. Aronson 46
Poliomyelitis, History and Probable Nature of the Virus of
Paul A. Lewis 46
Pontine Hemorrhage in a Subject, aged Twenty-eight Years
Fred D. Weidman 4
Pregnancy, Dermoid Cyst Complicating
F. B. Block 51
Pregnancy, Fibroid Tumor Complicating
B. M. Anspach and F. B. Block 50
Pyorrhea Alveolaris
John A. Roddy, Elmer H. Funk, and David W. Kramer 29

S

SARCOMA of the Rectum
John Speese 15
Sarcoma of the Right Frontal Lobe
George E. Price 38
Skin Cancer in a Gas-trap Cleaner
D. L. Farley and J. Harold Austin 16
Skin Cancer in Chimney-sweeps, Paraffin Workers and Allied Trades, etc.
Alfred Stengel and J. Harold Austin 22
Skin Reactions, The Effect of Certain Drugs upon
John A. Kolmer, Samuel L. Immerman, Toitsu Matsunami and Charles M. Montgomery 51
Splenectomy in Pernicious Anemia, The Value of Metabolic Studies for the Prognosis of
O. H. P. Pepper and J. H. Austin 34
Stamps, A Study of the Normal Bacterial Flora of
Robert A. Keilty and Philip D. McMaster 42
Syphilis and Tuberculosis in the Same Lung
Robert A. Keilty 7

Digitized by Google

T

THROMBOSIS of Aorta and Iliacs in a Horse
W. J. Crocker 40
Thyroid Gland, Changes following Intoxication by Toxic Protein Derivatives
A. L. Tatum and J. E. Sweet 22
Tissue Ferments, Experimental Studies in
E. Asnis, Anna Freese, and John A. Kolmer 33
Transparent Museum Preparation
W. J. Crocker 34
Tubal Pregnancy, Specimens of
George W. Outerbridge 30
Tubercle Bacilli, A Device for Protection Against the
Robert A. Keilty 40
Tubercle Bacilli, A Final Report on the Cultivation of, from the Sputum by the Method of Petroff
Robert A. Keilty 37
Tubercle Wax, Antigenic Properties of
Baldwin Lucke 36
Tuberculosis of the Kidney with Profuse Hemorrhage
F. E. Keene 47
Tuberculosis, Unilateral Renal, with Thickening of the Pelvic Ureter
J. Leon Herman 46

U

URINARY Calculi with Foreign Body Nuclei
W. M. L. Coplin 30
Uteri, Carcinosarcoma of
Geo. W. Outerbridge 31

V

VENOUS Metastasis, Retrograde, by Hypernephroma to Iliac Veins and Lumber Vertebræ
Fred D. Weidman 3
Ventricular Preponderance, Disproportionate Right, with Electrocardiographic Evidence
Edward B. Krumbhaar 49

Digitized by Google

INDEX TO AUTHORS.

A

ADDISON, WILLIAM H. F.
Fragmentation of the Ovum within the Graafian Follicle 1
Anspach, B. M., and F. B. Block
Fibroid Tumor Complicating Pregnancy 50
Aronson, J. D., and C. Y. White
The Use of Normal and Immune Serum in the Treatment of Poliomyelitis 46
Asnis, E., Anna Freese, and J. A. Kolmer
Experimental Studies in Tissue Ferments 33
Austin, J. H., and D. L. Farley
Skin Cancer in a Gas-trap Cleaner 16
Austin, J. H., and Alfred Stengel
Skin Cancer in Chimney-sweeps, Paraffin Workers and Allied Trades, etc. 22
Austin, J. H., and O. H. P. Pepper
The Value of Metabolic Studies for the Prognosis of Splenectomy in Pernicious Anemia 34
Austin, J. H., and Leon Jonas
Clinical Studies of Acidosis 41
Austin, J. H., and A. C. Wood
Observations on the Pathology of Early Hanot's Cirrhosis and of Weil's Disease 45

B

BLOCK, F. B., and T. H. Llewellyn
Hydrops Tubæ Profluens 16
Block, F. B.
Dermoid Cyst Complicating Pregnancy 51
Block, F. B., and B. M. Anspach
Fibroid Tumor Complicating Pregnancy 50
Bonney, C. N., and A. G. Ellis
Odontomas 27
Buckley, A. C., and D. Rivas
The Bacteriological Aspect of the Abderhalden Test 12

C

COPLIN, W. M. L.
Adrenals Showing Lesions Found in Pellagra 30

Digitized by Google

Coplin, W. M. L.
Urinary Calculi with Foreign Body Nuclei 30
Crocker, W. J.
A Transparent Museum Preparation 34
Crocker, W. J.
Thrombosis of Aorta and Iliacs in a Horse 40

D

Dorrance, Geo. M.
Fatty Tumor of Mesentery Causing Intestinal Obstruction . . . 17
Dry, D. M., and Thomas McCrae
Amebic Dysentery 25
Dry, D. M., and A. C. Morgan
Hypernephroma of the Lung Secondary to Hypernephroma of the Adrenals 26
Dry, D. M.
Congenital Aneurysmal Dilatation of Ductus Botalli 49

E

Ellis, A. G.
Carcinoma of Lung Stimulating Chorio-epithelioma 25
Ellis, A. G.
Giant-cell Glioma of Brain 25
Ellis, A. G., and C. N. Bonny
Odontomas 27
Ellis, A. G.
Classification of Leukocytes 52

F

Faber, Erwin F.
Various Methods of Illustration as Applied to Medical Works . . 11
Farley, D. L., and J. Harold Austin
Skin Cancer in a Gas-trap Cleaner 16
Fox, Herbert
Pigmentation of the Colon 35
Fox, Herbert, and F. B. Lynch
Effect of Nuclein on the Leukocytes of Dogs 39
Fox, Herbert, and F. B. Lynch
Leukocytes in Viridans Endocarditis and the Influence of Nuclein . 39
Fox, Herbert
Cretinism in Wolves 42
Francis, W. L., and Baldwin Lucke
Multiple Large Aneurysms 32
Freese, Anna, E. Asnis and J. A. Kolmer
Experimental Studies in Tissue Ferments 33

Digitized by Google

Funk, E. D.
Diverticulum of Esophagus 27
Funk, E. D.
Foreign Body (Roofing Nail) in Right Bronchus for Two and a Half Years 26
Funk, E. H., J. A. Roddy and D. W. Kramer
Pyorrhea Alveolaris 29
Funk, E. H., and J. P. Schaeffer
Massive Pleural Effusion 30
Funk, E. H., and J. P. Schaeffer
Hemothorax Due to Ruptured Aortic Aneurysm 30
Funk, E. H., and J. P. Schaeffer
Single Kidney 30

G

Gordon, Alfred
Gliomatous Tumor of the Brain 16

H

Haessler, Herbert and H. S. Newcomer
A Clinical Hemoglobinometer 19
Harkins, M. J., John A. Kolmer and Toitsu Matsunami
Bronchisepticin Skin Reaction 43
Harrison, F. G.
Experiments with the Bloch Method for Smegma Bacilli 44
Hartz, H. J., J. T. Leary and P. B. Hawk
A Preliminary Report upon the Toxicity of the Contents of Ovarian Cysts 33
Hawk, P. B., and Rehfuss, M. E.
A Study of the Cholesterol Content of the Serum in Gall-bladder Disease 28
Hawk P. B., J. T. Leary and H. J. Hartz
A Preliminary Report upon the Toxicity of the Contents of Ovarian Cysts 33
Henderson, Laurence J.
Acidosis 46
Herman, J. Leon
Specimen of Ruptured Right Kidney 47
Herman, J. Leon
Unilateral Renal Tuberculosis with Thickening of the Pelvic Ureter . 46
Hulton, Florence, and A. E. Taylor
The Formation of Specific Proteoclastic Ferments in the Blood in Response to the Parenteral Introduction of Foreign Proteins . . 23

I

Immerman, S. L., J. A. Kolmer, Toitsu Matsunami and C. M. Montgomery
The Effect of Certain Drugs upon Skin Reactions 51

Digitized by Google

J

JONAS, LEON and J. H. Austin
Clinical Studies of Acidosis 41

K

KEENE, F. E.
Congenital Vaginal Cysts 31
Keene, F. E.
Tuberculosis of the Kidney with Profuse Hemorrhage 47
Keilty, Robt. A., and P. D. McMaster
A Study of the Normal Bacterial Flora of Postage Stamps . . . 42
Keilty, Robt. A.
A Device for Protection against the Tubercle Bacilli 40
Keilty, Robt. A.
Two Cases of Papilloma of the Bladder 48
Keilty, Robt. A.
Fibro-adenorhabdomyomatous Mesothelioma of the Kidney . . . 8
Keilty, Robt. A.
Hydrocephalus the Result of Cyst of the Cerebellum 8
Keilty, Robt. A.
Syphilis and Tuberculosis in the Same Lung 7
Keilty, Robt. A.
Hydrochloric Acid as a Decolorizing Agent for the Tubercle Bacillus . 9
Keilty, Robt. A.
A Cardiac Formula for the Relative Measurements of the Valvular Orifices 9
Keilty, Robt. A.
A Leather-bottle Descending Colon, Sigmoid and Rectum 10
Keilty, Robt. A.
Primary Endothelioma of the Pleura 36
Keilty, Robt. A.
A Final Report on the Cultivation of the Tubercle Bacilli from the Sputum by the Method of Petroff 37
Keilty, Robt. A., and S. Paul Taylor
An Early Case of Eclampsia with Autopsy 48
Kern, Richard A., and Fred D. Weidman
Death at the Age of Twenty-two from Mesenteric Thrombosis, the Result of Arteriosclerosis with Terminal Peritonitis 4
Kolmer, John A., Jay F. Shamberg and Geo. D. Raiziss
The Numeric Relationship of Infection to the Chemotherapy of Experimental Trypanosomiasis 10
Kolmer, J. A., E. Asnis and Anna Freeze
Experimental Studies in Tissue Ferments 33
Kolmer, J. A., J. F. Shamberg and Geo. D. Raiziss
Various Methods for Determining the Trypanocidal Activity of Substances in Vitro and Their Relation to Chemotherapy of Experimental Trypanosomiasis 35

Digitized by Google

Kolmer, J. A., Toitsu Matsunami and Malcolm J. Harkins
The Relation of the Bronchisepticin Skin Reaction to Immunity in Canine Distemper Including the Bactericidal Action of Dog Serum for B. Bronchisepticus 43
Kolmer, J. A., S. L. Immerman, Toitsu Matsunami and C. M. Montgomery
The Effect of Certain Drugs upon Skin Reactions 51
Kramer, D. W., J. A. Roddy and E. H. Funk
Pyorrhea Alveolaris 29
Krumbhaar, E. B.
Disproportionate Right Ventricular Preponderance, with Electrocardiographic Evidence 49
Krumbhaar, E. B.
Four Types of Transient Heart-block Studied with Electrocardiograph 53

L

Langdon, R. H., and B. H. Lucke
Cholesteatoma Basis Cerebri 6
Leary, J. T., H. J. Hartz and P. B. Hawk
A Preliminary Report upon the Toxicity of the Contents of Ovarian Cysts 33
Lewis, Paul A.
History and Probable Nature of the Virus of Poliomyelitis . . . 46
Lindauer, E., and B. Lucke
Hypernephroma with Multiple Metastases 38
Llewellyn, T. H., and F. B. Block
Hydrops Tubæ Profluens 16
Lucke, Baldwin
A Pathologic Anatomic Analysis of Three Hundred Aneurysms Recorded in Thirteen Thousand Consecutive Autopsies 50
Lucke, B., and E. Lindauer
Hypernephroma with Multiple Metastases 38
Lucke, Baldwin
Antigenic Properties of Tubercle Wax 36
Lucke, Baldwin, and W. L. Francis
Multiple Large Aneurysms 32
Lucke, B. H., and R. H. Landon
Cholesteatoma Basis Cerebri 6
Lucke, Baldwin
Nephrolithiasis of a Cow 6
Lucke, Baldwin
Unusual Amyloid Kidney 5
Lucke, B. H., and Joseph McIver
Chondroma of the Pelvis 7
Lynch, F. B., and Herbert Fox
Leukocytes in Viridans Endocarditis and the Influence of Nuclein . 39
Lynch, F. B., and Herbert Fox
Effect of Nuclein on the Leukocytes of Dogs 39

Digitized by Google

M

MATSUNAMI, TOITSU, S. L. Immerman, J. A. Kolmer and C. M. Montgomery
The Effect of Certain Drugs upon Skin Reactions 51
Matsunami, Toitsu, J. A. Kolmer and Malcolm J. Harkins
Bronchisepticin Skin Reaction 43
McCrae, Thomas, and D. M. Dry
Amebic Dysentery 25
McIver, Jos., and B. H. Lucke
Chondroma of the Pelvis 7
McMaster, P. D., and Robt. A. Keilty
A Study of the Normal Bacterial Flora of Postage Stamps . . . 42
Miller, C. W., and A. E. Taylor
Studies in Bence-Jones Proteinuria 17
Montgomery, C. M., J. A. Kolmer, Toitsu Matsunami and S. L. Immerman
The Effect of Certain Drugs upon Skin Reactions 51
Morgan, A. C., and D. M. Dry
Hypernephroma of the Lung Secondary to Hypernephroma of the Adrenals 26

N

NEWCOMER, H. S., and Herbert Haessler
A Clinical Hemoglobinometer 19

O

ORTON, S. T.
Observations on the Influence of Angle of Section on Measurements of Cortex Depth and on the Cyto-architectonic Picture 24
Outerbridge, Geo. W.
Specimens of Tubal Pregnancy 30
Outerbridge, Geo. W.
Carcinosarcoma Uteri 31

P

PARK, WILLIAM H.
The Active and Passive Immunity against Diphtheria, Including a Discussion of the Schick Test 37
Peet, M. M., and J. E. Sweet.
The Fate of Large Quantities of Blood Introduced into the Peritoneal Cavity 21
Pelouze, P. S., and R. C. Rosenberger
Further Report upon Calcium and Parathyroid Medication in Tuberlous Guinea-pigs 29
Pepper, O. H. P., and J. H. Austin
The Value of Metabolic Studies for the Prognosis of Splenectomy in Pernicious Anemia 34
Pepper, O. H. P.
Chloride Retention without Edema; Report of a Probable Case . . 18

Digitized by Google

Piper, E. B.
Cesarean Section and Panhysterectomy for Carcinoma of the Cervix . 42
Price, George E.
Osteoma of the Falx Cerebri 38
Price, Geo. E.
Sarcoma of the Right Frontal Lobe 38
Price, Geo. E.
The Pathology of Poliomyelitis and Its Relation to the Virus . . . 46

R

Raiziss, Geo. D., J. A. Kolmer and J. F. Shamberg
Various Methods for Determining Trypanocidal Activity of Substances in Vitro and Their Relation to Chemotherapy of Experimental Trypanosomiasis 35
Raiziss, Geo. D., J. A. Kolmer and Jay F. Shamberg
The Numeric Relationship of Infection to the Chemotherapy of Experimental Trypanosomiasis 10
Randall, Alex.
Exhibition of Bladder and Prostatic Pathology 38
Rehfuss, M. E., and P. B. Hawk
A Study of the Cholesterol Content of the Serum in Gall-bladder Disease 28
Rivas, D., and A. C. Buckley
The Bacteriological Aspect of the Abderhalden Test 12
Roddy, J. A., E. H. Funk and D. W. Kramer
Pyorrhea Alveolaris 29
Rosenberger, R. C., and P. S. Pelouze
Further Report upon Calcium and Parathyroid Medication in Tuberculous Guinea-pigs 19
Rubenstone, A. J.
Visceral Amebiasis, with Report of a Case 39

S

Schaeffer, J. P., and E. H. Funk
Massive Pleural Effusion 30
Schaeffer, J. P., and E. H. Funk
Hemothorax Due to Ruptured Aortic Aneurysm 30
Schaeffer, J. P., and E. H. Funk
Single Kidney 30
Schamberg, J. F., J. A. Kolmer, and Geo. D. Raiziss
The Numeric Relationship of Infection to the Chemotherapy of Experimental Trypanosomiasis 10
Schamberg, J. F., J. A. Kolmer, and Geo. D. Raiziss
Various Methods for Determining the Trypanocidal Activity of Substances in Vitro and Their Relation to Chemotherapy of Experimental Trypanosomiasis 35
Schnabel, T. G.
The Clinical Significance of Bence-Jones Protein 18

Digitized by Google

Speese, John
Sarcoma of the Rectum 15
Speese, John
Papillary Carcinoma of the Stomach 13
Speese, John
Carcinomatous Degeneration of Papilloma of the Cecum 15
Speese, John
Myxosarcoma of the Mesentery 14
Stengel, Alfred, and J. H. Austin
Skin Cancer in Chimney-sweeps, Paraffin Workers and Allied Trades . 22
Strickler Albert
Differential Blood Pictures in Parasitic Skin Diseases and Their Possible Significance 20
Sweet, J. E., and A. L. Tatum
Changes in the Thyroid Gland following Intoxication by Toxic Protein Derivatives 22
Sweet, J. E., and M. M. Peet
The Fate of Large Quantities of Blood Introduced into the Peritoneal Cavity 21

T

Tatum, A. L., and J. E. Sweet
Changes in the Thyroid Gland following Intoxication by Toxic Protein Derivatives 22
Taylor, A. E.
Some Lessons of the War on the High Cost and High Plane of Living . 1
Taylor, A. E., and C. W. Miller
Studies in Bence-Jones Proteinuria 17
Taylor, A. E., and Florence Hulton
The Formation of Specific Proteoclastic Ferments in the Blood in Response to the Parenteral Introduction of Foreign Proteins . . 23
Taylor, S. Paul, and Robt. A. Keilty
An Early Case of Eclampsia with Autopsy 48

W

Weidman, Fred D.
A Method of Obtaining Duplicate Reconstructions from the One Series of Wax Plates 44
Weidman, Fred D.
Hyperplastic Bone Formation under Old Mammary Operative Site . 5
Weidman, Fred D., and R. A. Kern
Death at the Age of Twenty-two from Mesenteric Thrombosis, the Result of Arteriosclerosis with Terminal Peritonitis 4
Weidman, Fred D.
Pontine Hemorrhage in a Subject, Aged Twenty-eight Years . . . 4
Weidman, Fred D.
Retrograde Venous Metastasis by Hypernephroma to Iliac Veins and Lumbar Vertebræ 3

Digitized by Google

Weidman, Fred D.
Massive Hemorrhage of Adrenal in Adult, aged Sixty-four Years . . 3
Weidman, Fred D.
Accessory Pancreases (Two) in Wall of Jejunum 2
Weidman, Fred D.
Aberrant Cerebellar Tissue in Occipital Bone 2
White, C. Y., and J. D. Aronson
The Use of Normal and Immune Serum in the Treatment of Poliomyelitis 46
Wolferth, C. A.
A Study of Chloride Retention in Nephritis and Eclampsia 41
Wolferth, C. C.
The Clinical Importance of Chloride Retention 19
Wood, A. C., and J. H. Austin
Observations on the Pathology of Early Hanot's Cirrhosis and of Weil's Disease 45

Digitized by Google

Digitized by Google

Digitized by Google

Digitized by Google

41B
110+

HOLZER BINDER MASS.

Digitized by Google

3 204